

Efficacy of Dexamethasone Implant versus Intravitreal Ranibizumab Treatment for Chronic Diabetic Macular Edema in Type 2 Diabetic Patients

Tip 2 Diyabetik Hastalarda Kronik Diyabetik Makula Ödem Tedavisinde Dekametazon İmplant ve İntravitreal Ranibizumab'ın Etkinliğinin Karşılaştırılması

Erdoğan AYDIN¹, Naciye AYĞÜN KARABOĞA², Emine DENİZ EĞRİLMEZ³, Levent KAZANCI³

ABSTRACT

Purpose: To evaluate the efficacy of an intravitreal dexamethasone (DEX) implant versus intravitreal ranibizumab (RAN) for chronic diabetic macular edema (DME) in Type 2 Diabetic Patients.

Materials and Methods: In this retrospective, comparative, cohort study, 28 eyes of 22 patients were received DEX implant at every 24 weeks. Thirty-seven eyes of 30 patients were performed RAN injections on pro re nata (PRN), immediately after three loading doses. Main outcome measures included best-corrected visual acuity (BCVA) and central macular thickness (CMT), intraocular pressure (IOP) and incidence of side effects in both groups.

Results: The mean change of BCVA for 12 months was -0, 11 Log MAR in DEX group and -0, 55 Log MAR in RAN group. There was a statistically significant difference in BCVA between the DEX group and RAN group at month 6 and month 12 ($p=0.0001$ and $p=0.0001$). Mean CMT was significantly decreased in both groups from the baseline to month 6 and month 12 (DEX: $p=0.001$ and $p=0.0001$, RAN: $p=0.0001$, $p=0.0001$). Mean changes of CMT for 6 months and 12 months were -80 μ m and -127 μ m with the DEX group, and -204 μ m and -227 μ m with the RAN group. Mean IOP increased remarkably in the DEX group compared to the RAN group. However, 7 eyes with IOP higher than 21 mmHg were well controlled with topical anti-glaucoma drugs in DEX group.

Conclusion: The study demonstrated that more preferable functional and anatomic outcome could be provided by RAN injection than DEX implant for 12 months. BCVA and CMT improved significantly as soon as one month and up to 4 months in DEX implant treatment, but were not maintained as well as RAN treatment.

Key Words: Dexamethasone implant, diabetic macular edema, diabetic retinopathy, ranibizumab.

ÖZ

Amaç: Tip 2 diyabetik hastalarda kronik diyabetik makula ödemi (DMÖ) tedavisinde intravitreal ranibizumab (RAN) ile intravitreal deksametazon (DEX) implantı'nın etkinliğini değerlendirmek.

Materyal ve Metot: Bu retrospektif, karşılaştırmalı, kohort çalışmada, 22 hastanın 28 gözüne her 24 haftada bir DEX implant ve 30 hastanın 37 gözüne, üç yükleme dozundan hemen sonra pro re nata (PRN) protokolüne uygun olarak RAN enjeksiyonu yapıldı. İki grupta, en iyi düzeltilmiş görme keskinliği (EDGK), merkezi makula kalınlığı (MMK), göz içi basıncı (GİB) değerleri ve yan etkiler açısından karşılaştırıldı.

Bulgular: On iki aylık EDGK ortalama değişimi DEX grubunda -0, 11 Log MAR ve RAN grubunda -0,55 Log MAR olarak bulundu. DEX grubu ile RAN grubu arasında 6. ay ve 12. ayda EDGK'da istatistiksel olarak anlamlı fark vardı ($p=0.0001$ ve $p=0.0001$). Ortalama MMK, başlangıç değerlerine göre her iki grupta da 6. ay ve 12. ayda (DEX: $p=0.001$ ve $p=0.0001$, RAN: $p=0.0001$, $p=0.0001$) anlamlı şekilde azaldı. MMK'nın 6 ay ve 12 aylık ortalama değişiklikleri -80 μ m ve -127 μ m idi. DEX grubu ve RAN gruplarında sırasıyla -204 μ m ve -227 μ m ola-

1- Prof. Dr., İzmir Katip Çelebi Üniversitesi, Göz AD, İzmir, Türkiye

2- Uz. Dr., Gaziemir Devlet Hastanesi, Göz Kliniği, İzmir, Türkiye

3- Uz. Dr., İzmir Katip Çelebi Üniversitesi Atatürk Eğitim ve Araştırma Hastanesi, Göz Kliniği, İzmir, Türkiye

Geliş Tarihi - Received:

Kabul Tarihi - Accepted:

Ret-Vit 2019; 28: 25-31

Yazışma Adresi / Correspondence Address:

Erdoğan AYDIN

İzmir Katip Çelebi Üniversitesi, Göz AD, İzmir, Türkiye

Tel: +90 232 244 4444

E-mail: erdincaydin@yahoo.com

rak bulundu. Ortalama GİB, DEX grubunda RAN grubuna göre belirgin olarak arttı. Bununla birlikte, GİB 21 mmHg' dan yüksek olan DEX grubundaki 7 gözdeki basınç topikal anti-glokomatöz ilaçlarıyla kontrol altına alındı.

Sonuç: Bu çalışmada, 12 ay boyunca RAN enjeksiyon tedavisi ile DEX implantasyonuna göre tercihen daha iyi fonksiyonel ve anatomik sonuçlar görüldü. EDGK ve MMK da, DEX implant tedavisinde bir aydan kısa bir sürede belirgin şekilde iyileşme izlenmesine rağmen, 4 aydan sonra RAN tedavisinde olduğu gibi devamlılık sağlanamamıştır.

Anahtar Kelimeler: Dekzametazon implant, diyabetik makular ödem, diyabetik retinopati, ranizumab.

INTRODUCTION

Diabetic macular edema (DME) is one of the major causes of visual impairment in patients with diabetic retinopathy.^{1,2} In Europe and the United States, 7%–12% and 1%–3% of the diabetic population suffers from visual impairment due to DME.³

Diabetic macular edema results from the exudation and accumulation of extracellular fluid and proteins in the macula due to the breakdown of the blood-retina barrier (BRB), leukocytosis and expression of inflammatory factors, such as VEGF, intercellular adhesion molecule-1, tumor necrosis factor- α , and interleukin-6; and alterations in endothelial tight junction proteins.^{4,5} The increased levels of inflammatory mediators 'results in Muller cell dysfunction owing to intracellular fluid accumulation and retinal edema. The inflammatory mediators and glutamate may lead to disruption of the inner nuclear layer and cell death.⁶

Focal and grid laser photocoagulation therapy can be applied for micro aneurysms and areas of diffuse leakage to reduce DME.^{7,8} Intravitreal anti-VEGF agents have also disclosed remarkable benefit in DME, as reported in long-term outcomes of RAN therapy for diabetic macular edema; as shown in two phase III trials over 36 months: RISE and RIDE⁹ and a prospective randomized trial of intravitreal bevacizumab or laser therapy in the management of diabetic macular edema (BOLT study) 12-month data: report 2.¹⁰

Anti-VEGF agents directly inhibit the activity of vascular permeability factor (VEGF); however, corticosteroids decrease the production and release of VEGF and also proinflammatory cytokines, and support the barrier function of vascular tight junctions.^{11,12} Intravitreal corticosteroids block the production of inflammatory mediators, such as VEGF, and inhibit leukostasis.^{12,13} Dexamethasone is an anti-inflammatory agent that is six-times more active than triamcinolone and 30-times more than cortisol. In 2014, a sustained-release intravitreal 0.7 mg dexamethasone delivery system was approved by Food and Drug Administration (FDA) and Commission Européenne (CE) for the treatment of DME, based on the MEAD study results. Boyer et al. reported its efficacy and safety in the treatment of DME when delivered to the vitreous cavity by a sustained-release intravitreal implant.¹⁴

The aim of this study was to assess the efficacy and safety profile of an intravitreal dexamethasone (DEX) implant ver-

sus intravitreal ranibizumab (RAN) for chronic DME and detect the long-term effects of the drugs.

MATERIALS AND METHODS

Patients with NPDR or PDR for whom laser photocoagulation and intravitreal RAN or DEX implant injection were considered necessary and performed between Jan 2013 and May 2016 were enrolled in this study. This study was approved by the local ethics committee and was conducted in accordance with the Declaration of Helsinki. Informed consent was obtained from all patients before injection. All collected data were evaluated retrospectively.

All patients underwent cardiological examination, electrocardiogram, and blood tests that included glycosylated hemoglobin (HbA1c) following preoperative anamnesis. Informed consent was obtained from all patients prior to the injection. Initially, all patients included in the study underwent a complete ophthalmic examination, including BCVA (log MAR), intraocular pressure (IOP) measurement by Prismatic applanation, and fundus fluorescein angiography (FFA). Central foveal thickness (CFT) was measured by spectral domain OCT (Cirrus 4000, HD-OCT, Carl Zeiss Meditec Inc., Dublin, CA) and the presence of a retinal thickness greater than 275 μ m was confirmed.

In this retrospective, study included all patients who had chronic DME (unilateral or bilateral) and Type 2 Diabetes Mellitus. Sixty-five eyes of 52 patients with chronic DME (over 275 micrometers) were divided into two groups: (28 eyes of 22 patients) DEX group (0.7 mg); and (37 eyes of 30 patients) RAN group (0.5 mg/0.05 ml).

In the RAN group, three monthly (loading dose) then 0.5 mg dose PRN dosing was maintained (ranibizumab injections were given every four weeks up to week 12 and on a pro re nata (PRN or 'as needed' basis'). In DEX implant group, the patients were received implant on every 24 weeks.

Inclusion criteria were: over 18 years old, best-corrected visual acuity (BCVA) between 1.22 and 0.4 logarithms of the minimal angle of resolution (log MAR), and chronic DME. Chronic DME is defined as DME present for a period of 6 months or more with CFT greater than 275 microns as measured by spectral-domain optical coherence tomography (SD-OCT).^{9,10,14}

Patients were excluded if they had a history of uveitis (in either eye), history of glaucoma, evidence of either vitreo-

macular traction (in either eye) or active proliferative diabetic retinopathy (study eye), hypertension uncontrolled by medication, pregnancy, severe cataract, venous occlusions by SD-OCT, age-related macular degeneration, history of cataract surgery (within the previous six months), YAG laser capsulotomy (within 6 months prior to the trial), previous vitrectomy, panretinal or grid laser photocoagulation (within 6 months prior to investigation), incompliance with follow-up periods. All patients were previously treated with anti-VEGF.

All the injections were given according to a standardized procedure in an operating room. DEX implant (0.7-mg implant of dexamethasone, Ozurdex; Allergan, Inc. Irvine, CA) was administered intravitreally through the pars plana using the original implanting device. After the administration, IOP and light perception were assessed. Complete ophthalmic examination, including IOP measurements was performed at the initial and per months. The main outcomes were the changes between the initial and follow-up visits in the mean BCVA, CFT, and IOP measures.

Statistical analysis

The examination of whether BCVA, CFT, and IOP measurements at baseline, first week, and per month satisfied the underlying assumptions of parametric statistical tests such as normality across groups and homogeneity of the group variances using Shapiro-Wilk and Levene's tests indicated that normality assumption was mostly violated by the data whereas the homogeneous group variances were present. Therefore, nonparametric statistical tests were utilized for between-groups comparisons at each time point and within-groups time comparisons.

For between-groups comparisons, Mann-Whitney-U tests were done to compare DEX implant and RAN groups on VA, CFT, and IOP measurements at each time point. Wil-

coxon tests were used to compare differences between pre- and post-injection values of all the parameters evaluated and obtained at different follow-up points (at month 1–12) within groups as follow-up tests once a statistically significant Friedman test was obtained. Pearson's correlation coefficients were used to evaluate the linear association between BCVA and CFT. All data are descriptively presented as the mean \pm standard deviation (SD) in tables. Statistical tests were evaluated at the nominal alpha levels with Bonferroni adjustment. Statistical calculations were performed using SPSS (version 18.0; SPSS Inc., Chicago, IL). All data are presented as the mean \pm standard deviation (SD). Differences were statistically significant when $p < 0.05$.

RESULTS

Sixty-five eyes of 52 patients with chronic DME were included and analyzed as DEX implant group (9 males, 13 females; mean age 60.67 ± 10.17 years, range 44–82 years old) and RAN (15 males, 15 females; mean age 58.5 ± 12.6 years, range 41–77 years old). The duration of DM was 13.82 ± 6.67 years (range 4–27 years) for the DEX implant group, and 12.33 ± 5.68 years (range 4–25 years) for the RAN group. The mean HbA1c value at baseline was $7.32 \% \pm 0.85$ (range 6–8.6) for the DEX implant group, and $7.15 \% \pm 0.90$ (range 5.2–8.9) for the RAN group. In the DEX implant group, 8 eyes had previous grid laser, and 7 eyes had scatter laser treatment. In the RAN group, 10 eyes had previous grid laser, and 7 eyes had scatter laser treatment. Prior to the study, the numbers and intervals of the intravitreal RAN injections were 4.02 ± 1.11 (range 3–7) and 1.55 ± 0.24 (range 1, 16–2, 4) in the RAN group, 4.03 ± 0.099 (range 3–6) and 1.49 ± 0.16 (range 1, 13–1, 75) in the DEX implant group, respectively. During the study, the numbers of the intravitreal RAN injections were 9.02 ± 1.11 (range 8–12) in the RAN group. Pre-study and follow-up period, FFA showed no cases of macular or perifoveal retinal ischemia (Table 1).

Table 1. Demographic and clinic characteristic of DEX implant group and RAN group.

	DEX (n=28)	RAN(n=37)	p-value
Eye (R/L)	15/13	21/16	*0,800
Age (years, mean \pm SD)	58,2 \pm 13.7	60.2 \pm 8.5	*0,958
Gender (M/F)	9/13	15/15	*0,271
Phakic/Pseudophakic	23/5	31/6	*0,862
DM (years, mean \pm SD)	14.71 \pm 6.27	12.27 \pm 5.90	*0,132
HbA1c (% , mean \pm SD)	7.32 \pm 0.85	7.15 \pm 0,90	*0,399
NPDR/PDR	21/7	30/7	*0.558
Hypertansion	6	7	*0,782
RAN prior to study (mean \pm SD)	4,03 \pm 0,99	4,02 \pm 1,11	*0,839
RAN during study (mean \pm SD)		9,02 \pm 1,11	

DM: diabetes mellitus, **DME:** diabetic macular edema, **SD:** standart deviation, **RAN:** ranizumab;, **R:** right **L:** left, **M:** male, **F:** female, **NPDR:** nonproliferative diabetic retinopathy, **PDR:** nonproliferative diabetic retinopathy , **Ki-kare test, *Mann-Whitney U test

The mean BCVA in the DEX implant and RAN groups were 0.83 ± 0.18 log MAR vs. 0.75 ± 0.22 log MAR at baseline, 0.56 ± 0.13 log MAR vs. 0.69 ± 0.23 log MAR at 1st month, 0.50 ± 0.12 log MAR vs. 0.62 ± 0.21 log MAR at 2nd month, 0.55 ± 0.12 vs. 0.55 ± 0.19 at 3rd month, 0.61 ± 0.12 log MAR vs. 0.52 ± 0.20 log MAR at 4th month, 0.70 ± 0.11 log MAR vs. 0.45 ± 0.19 log MAR at 5th month, 0.74 ± 0.13 log MAR vs. 0.42 ± 0.15 log MAR at the 6th month, 0.46 ± 0.10 log MAR vs. 0.36 ± 0.12 log MAR at 7th month, 0.50 ± 0.02 log MAR vs. 0.34 ± 0.11 log MAR at 8th month, 0.55 ± 0.02 log MAR vs. 0.29 ± 0.11 log MAR at 9th month, 0.60 ± 0.01 log MAR vs. 0.24 ± 0.10 log MAR at 10th month, 0.66 ± 0.02 log MAR vs. 0.21 ± 0.09 log MAR at 11th month and 0.69 ± 0.02 log MAR vs. 0.20 ± 0.08 log MAR at the 12th month, respectively (Figure. 1). There was a statistically significant difference in visual acuity between the DEX implant group and RAN group except at 3rd month ($p = 0.578$).

The mean CFT in the DEX implant and RAN groups

were $524.2 \pm 143.6 \mu\text{m}$ vs. $466.1 \pm 136.7 \mu\text{m}$ at baseline, $342.3 \pm 133.7 \mu\text{m}$ vs. $347.2 \pm 83.9 \mu\text{m}$ at 1st month, 289.7 ± 115.4 vs. $340.7 \pm 81.8 \mu\text{m}$ at 2nd month, $275.5 \pm 87.7 \mu\text{m}$ vs. $328.7 \pm 77.2 \mu\text{m}$ at 3th month, 267.2 ± 62.3 vs. 244.9 ± 29.2 at 4th month, 317.3 ± 65.4 vs. 240.2 ± 36.1 at 5th month, $444.3 \pm 108.5 \mu\text{m}$ vs. $261.5 \pm 32.2 \mu\text{m}$ at 6th month, 341.3 ± 80.9 vs. $241.8 \pm 28.7 \mu\text{m}$ at 7th month, $293.3 \pm 60.7 \mu\text{m}$ vs. $241.9 \pm 34.2 \mu\text{m}$ at 8th month, $261.8 \pm 54.8 \mu\text{m}$ vs. $250.3 \pm 29.7 \mu\text{m}$ at 9th month, $256.9 \pm 56.9 \mu\text{m}$ vs. $236.6 \pm 32.8 \mu\text{m}$ at 10th month, $304.7 \pm 51.7 \mu\text{m}$ vs. $240.2 \pm 40.1 \mu\text{m}$ at 11th month, $397.6 \pm 44.3 \mu\text{m}$ vs. $239 \pm 33.9 \mu\text{m}$ at 12th month, respectively (Figure. 1). Mean changes of CFT for 6 months and 12 months were $79.9 \mu\text{m}$ and $126.6 \mu\text{m}$ with the DEX implant group, and $56.9 \mu\text{m}$ and $227.1 \mu\text{m}$ with the RAN group (Table 1, Figure 2). A rebound of macular edema was observed between month 5 and month 6, month 11 and month 12 in the DEX implant group (Table 1). BCVA and CFT figures had tendency as biphasic line in DEX implant group.

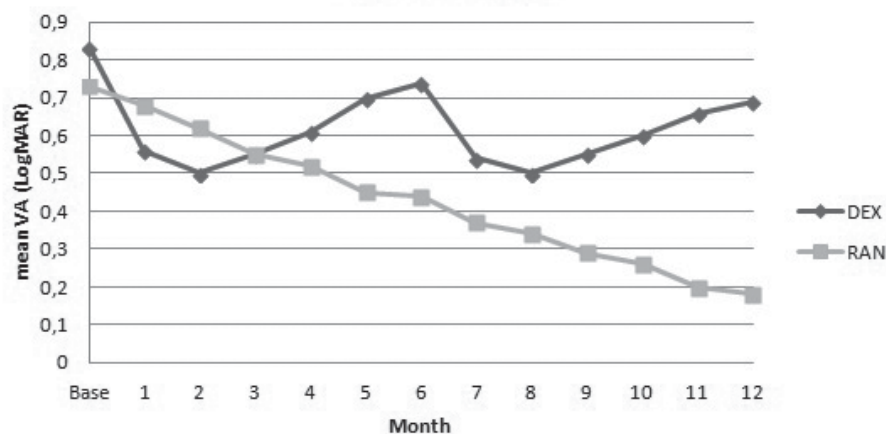


Figure 1. Graph showing changes in mean BCVA from baseline over 12 months, during treatment with intravitreal ranibizumab (RAN) or dexamethasone implant (DEX).

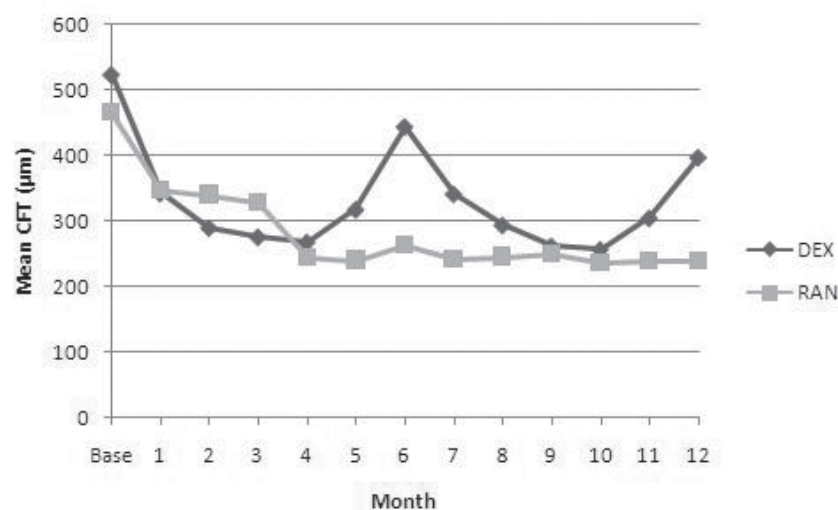


Figure 2. Central Foveal Thickness Changes following DEX implant and intravitreal RAN.

The mean IOP in the DEX implant and RAN groups were $14,9 \pm 1,4$ mmHg vs. $14,9 \pm 1,7$ mmHg at baseline, $20,3 \pm 3,2$ mmHg vs. $16,2 \pm 2,0$ mmHg at 1st month, $20,2 \pm 3,4$ mmHg vs. $15,8 \pm 1,8$ mmHg at 2nd month, $19,2 \pm 3,6$ mmHg vs. $16,0 \pm 1,5$ mmHg at 3rd month, $18,1 \pm 1,8$ mmHg vs. $15,9 \pm 1,6$ mmHg at 4th month, $17,3 \pm 1,4$ mmHg vs. $15,9 \pm 1,5$ mmHg at 5th month, $16,7 \pm 1,3$ mmHg vs. $15,8 \pm 1,4$ mmHg at 6th month, $19,6 \pm 1,8$ mmHg vs. $16,0 \pm 1,2$ mmHg at 7th month, $19,2 \pm 2,5$ mmHg vs. $15,5 \pm 1,5$ mmHg at 8th month, $18,9 \pm 2,5$ mmHg vs. $15,1 \pm 1,3$ mmHg at 9th month, $18,0 \pm 1,7$ mmHg vs. $16,3 \pm 1,3$ mmHg at 10th month, $17,1 \pm 1,5$ mmHg vs. $16,0 \pm 1,3$ mmHg at 11th month, $16,7 \pm 1,2$ mmHg vs. $15,7 \pm 1,1$ mmHg at 12th month, respectively.

There was significantly increased IOP from baseline to 12th month in the DEX implant group but not increased IOP at month 6, at month 8, at month 9 and at month 12 in the RAN group (Figure 3). During the follow-up period, we have found IOP higher than 21 mmHg in 7 eyes (25 %) of the DEX implant group. These eyes were treated and controlled with topical anti-glaucoma therapy. Cataract progression was observed in 2 cases of DEX implant group during the follow-up. There was no inflammation, infection, thrombo-embolic events, ocular toxicity, or cataract progression observed in any of the patients in RAN group.

Pearson correlation showed positive relation between BCVA and CFT at 3th month in DEX implant group ($p=0,389$, $r=-0,41$), but there was no relation in RAN group.

DISCUSSION

In this study, intravitreal RAN treatment looked like superiority to DEX implant treatment in average change from baseline BCVA over 12 months when DEX implant was administered every 6 months and RAN injections was applied on pro re nata (PRN). At the follow-up, we found that intra-

vitreal RAN injection demonstrated highly effectively for the treatment of chronic DME. The improvement of BCVA looked like to start at the first month and reached a peak level between second month and 3th month, then decreased after 3th month. In the other hand, the regression of CFT evolved at the first month and reduced after 4th month and 10th month. This result might be linked to reduced release of the drug rather than diabetic dysregulation since all included patients in both groups had lower than mean HbA1c values of 8.0 %. However, FFA did not demonstrate any ischemia during follow-up.

In clinical practice, intravitreal steroids are rarely preferred as the initial treatment due to the ocular side effects. If there is any contraindication about anti-VEGF treatment or in-compliance with patients, steroid implants can be considered for DME.

Lazic and coworkers evaluated the efficiency of intravitreal dexamethasone implant in patients with chronic DME unresponsive to three monthly 1.25 mg intravitreal bevacizumab injections and reported significant improvement in BCVA at month 2 and in CFT at month 1, 2 and 3.¹⁵ Zucchiatti and coworkers demonstrated that in eyes with chronic DME,

In the other hand, a single intravitreal Ozurdex implant could produce improvement in BCVA and CFT as soon as the first day after the injection, and such improvement was maintained until the fourth month.¹⁶

Gillies and coworkers reported in one-year results of a BEVORDEX study that 42 eyes were randomized to receive bevacizumab every 4 weeks and 46 eyes were randomized to receive a dexamethasone implant every 16 weeks. The mean improvement in BCVA was 8.9 letters (95% confidence interval, 6.27-11.6) for bevacizumab-treated eyes and 5.6 letters (95% confidence interval, 0.90-10.3) for dexamethasone implant treated eyes by the 12-month visit. The

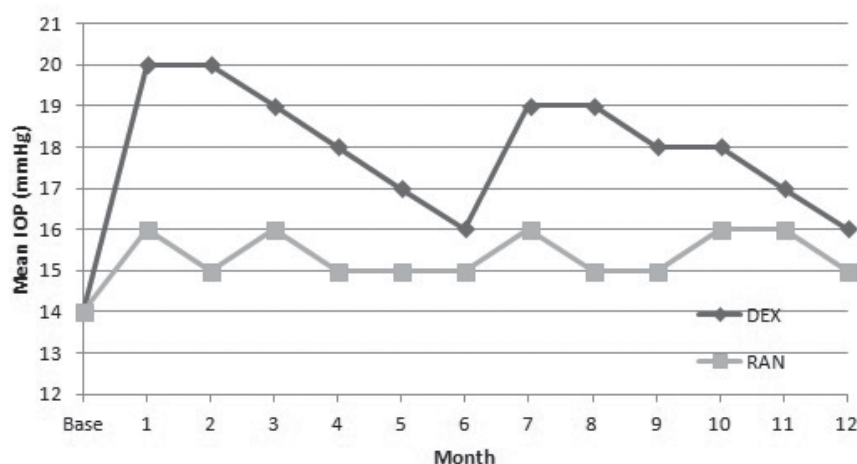


Figure 3. Intraocular Pressure Changes following DEX implant and intravitreal RAN

difference between two groups was not statistically significant ($p = 0.24$). Mean CFT decreased by 122 mm for bevacizumab eyes and by 187 mm for dexamethasone implant eyes ($p = 0.015$). According to published two years results of the BEVORDEX study, eyes continued on the same treatment allocation. The VA improvement seen at 12 months in both group was maintained at 24 months, with 20 of 46 DEX-implant-treated eyes (43%) and 19 of 42 bevacizumab-treated eyes (45%) achieving > 10 letter VA gain ($p = 0.99$). There was no difference between the CFT of groups at 24 months.^{17, 18}

Maturi and coworkers found that combination therapy with bevacizumab and the dexamethasone delivery system (DDS) reduces the central retinal thickness (CRT) significantly better (-45 ± 107 mm vs. -30 ± 100 mm; $p = 0.03$) compared with continued bevacizumab monotherapy while achieving similar visual outcomes ($+5.4$ letters vs. $+4.9$ letters) at 1 year.¹⁹

Totan and coworkers reported in their study about efficacy of DEX implant in patients with chronic diabetic macular edema resistant to intravitreal bevacizumab treatment where BCVA significantly ($p = 0.04$) decreased at 6th month (0.59 ± 0.39 log MAR) compared to the mean BCVA at 3 month (0.44 ± 0.28 log MAR). At the 6th month visit, the mean CFT (411 mm, range 174–776 mm) ($p < 0.001$) was still significantly lower compared to the baseline value (517 mm, range 324–872 mm) ($p = 0.01$), but significantly increased compared to the mean CFT at 3rd month (314 mm, range 186–758 mm).²⁰

Cerman and coworkers presented in the study of DEX implant in patients with persistent diabetic macular edema that the highest mean BCVA gain (0.58 ± 0.36 log MAR) and central foveal flattening (286.9 ± 79.9 mm) was at first month, but there were no significant differences (0.88 ± 0.43 log MAR, 0.70 ± 0.43 log MAR; 577.6 ± 265.8 mm, 414.3 ± 157.5 mm) at the 6th month and 12th month visits compared to baseline value (0.76 ± 0.37 log MAR, 518.0 ± 149 mm).²¹

Callanan and coworkers declared that mean average BCVA change from baseline over 12 months was 4.34 letters with DEX implant versus 7.60 letters with ranibizumab. Kaplan–Meier analysis of time to achievement of ≥ 15 -letter BCVA improvement showed that patients in the DEX implant group usually achieved their initial ≥ 15 -letter BCVA gain within 4 months after their first DEX implant treatment. At month 12, the mean change from baseline CRT was similar in the DEX implant and ranibizumab groups (-173.9 and -163.5 μ m respectively).²²

In our study, there were 21 eyes (56.7%) with baseline VA (≤ 0.7 Log MAR) in the RAN group and 26 eyes (92.8%) with baseline VA (≤ 0.7 Log MAR) in the DEX implant group. BCVA improvements of 21 eyes in RAN group were 6 eyes (1 line), 5 eyes (2 lines), one eye (3 lines), and one eye (4

lines) at the 6th month. Three eyes (4 line), 6 eyes (5 line), 2 eyes (6 line), 2 eyes (7 line), 3 eyes (8 line), 2 eyes (9 lines) at the 12th month. BCVA improvement of 26 eyes in DEX group were 9 eyes (1 line), 3 eyes (2 lines), one eye (4 lines), one eye (5 line) at the 3rd month and 3 eyes (1 line), one eye (2 lines), one eye (3 lines), one eye (4 lines), one eye (5 lines) at the 6th month and 8 eyes (1 line), 6 eyes (2 line), 4 eyes (3 line) at the 12th month.

The GENEVA study showed that an intravitreal DEX implant was associated with a low ocular risk profile.²³ In the present study; glaucoma was detected in 8 patients of the DEX group, and was under control with topical medication. Cataract progression was observed in 2 cases of DEX group during the follow-up. There were no observed adverse effects including inflammation, infection, thromboembolic events, or ocular toxicity regarding the use of intravitreal DEX implant.

The effectiveness of a PRN regimen in DMO has been established with ranibizumab 0.5 mg (Lucentis®; Genentech, South San Francisco, California, USA; and Novartis Pharma AG, Basel, Switzerland) in the long-term RESTORE and DRCR.net (protocol I) studies. In these studies, the initial best-corrected visual acuity (BCVA) improvements observed at year 1 were maintained through years 2, 3 and 5, with a reduced number of injections.^{24, 25}

This study was limited by a retrospective cohort design, small number of non-naïve patients, DEX injections at per six months, differences of baseline VA rates between groups.

Consequently, DEX implant therapy seems not to be as effective as intravitreal RAN therapy. DEX implant group could not maintain BCVA and CFT as well as intravitreal RAN group due to deferred DEX implant treatment. DEX therapeutic regimens should be customized for patients needs prior to at 5th month as every 16 weeks. Further clinical trials are comparatively required to define the effect of intravitreal DEX implant and intravitreal RAN injections in a larger series with longer follow-up.

Acknowledgements

This research received no specific grant from any funding agency in the public, commercial, or non-profit sectors. We owe special thanks to Assistant Professor Dr. Bulent Ozkan PhD, Department of Biostatistics for helping with statistically evaluation of the study.

Conflict of interest

No conflict of interest was declared by the authors.

Financial Disclosure

The authors declared that this study received no financial support.

KAYNAKLAR / REFERENCES

1. Resnikoff S, Pascolini D, Etya'ale D, et al. Global data on visual impairment in the year. *Bull World Health Organ* 2004; 82:844–51.
2. Klein R, Klein BE, Moss SE, Cruickshanks KJ. The Wisconsin Epidemiologic Study of Diabetic Retinopathy: XVII. The 14-year incidence and progression of diabetic retinopathy and associated risk factors in type 1 diabetes. *Ophthalmology* 1998; 105(10): 1801–15.
3. Chen E, M. Looman, M. Laouri et al. Burden of illness of diabetic macular edema: literature review, *Current Medical Research & Opinion* 2010; 26(7); 1587–97.
4. Funatsu H, Noma H, Mimura T, Eguchi S, Hori S. Association of vitreous inflammatory factors with diabetic macular edema. *Ophthalmology* 2009; 116 (1):73–9.
5. Wang J, Xu X, Elliott MH, Zhu M, Le YZ. Müller cell-derived VEGF is essential for diabetes-induced retinal inflammation and vascular leakage. *Diabetes*; 2010; 59(9): 2297–305.
6. Abcouwer SF. Angiogenic factors and cytokines in diabetic retinopathy. *J Clin Cell Immunol Suppl* 2013; 11–2.
7. Early Treatment Diabetic Retinopathy Study Research Group. *Arch Ophthalmol*. 1985; 103:1796–806.
8. Diabetic Retinopathy Clinical Research Network. A randomized trial comparing intravitreal triamcinolone acetonide and focal/grid photocoagulation for diabetic macular edema. *Ophthalmology*; 2008; 115(9):1447–9.
9. Brown DM, Nguyen QD, Marcus DM, et al. Long-term outcomes of ranibizumab therapy for diabetic macular edema: the 36-month results from two phase III trials: RISE and RIDE. *Ophthalmology*. 2013; 120:2013–22.
10. Michaelides M, Kaines A, Hamilton RD, et al. () A prospective randomized trial of intravitreal bevacizumab or laser therapy in the management of diabetic macular edema (BOLT study) 12-month data: report 2. *Ophthalmology*. 2010; 117:1078–86.
11. Tamura, H., Miyamoto, K., Kiryu, J. et al. Intravitreal injection of corticosteroid attenuates leukostasis and vascular leakage in experimental diabetic retina. *Invest Ophthalmol Vis Sci*. 2005; 46:1440–4.
12. Felinski EA, Antonetti DA. Glucocorticoid regulation of endothelial cell tight junction gene expression: novel treatments for diabetic retinopathy. *Curr Eye Res*; 2005; 30:949–57.
13. Boyer DS, Yoon YH, Belfort R Jr, Bandello F, Maturi RK, Augustin AJ, et al. Three-year, randomized, sham-controlled trial of dexamethasone intravitreal implant in patients with diabetic macular edema. *Ophthalmology*. 2014; 121(10):1904–14.
14. Diabetic Retinopathy Clinical Research Network. A phase II randomized clinical trial of intravitreal bevacizumab for diabetic macular edema. *Ophthalmology* 2007; 114: 1860–67.
15. Lazic R, Lukic M, Boras I, et al. Treatment of anti-vascular endothelial growth factor resistant diabetic macular edema with dexamethasone intravitreal implant. *Retina* 2013; 34:719–24.
16. Zucchiatti I, Lattanzio R, Queques G, et al. Intravitreal dexamethasone implant in patients with chronic diabetic macular edema. *Ophthalmologica*. 2012; 228:117–22.
17. Gillies MC, Lim LL, Campain A et al. A randomized clinical trial of intravitreal bevacizumab versus intravitreal dexamethasone for diabetic macular edema: the BEVORDEX study. *Ophthalmology* 2014; 121(12):2473–81.
18. Fraser-Bell S, Lim LL, Campain A. et al. Bevacizumab or Dexamethasone Implants for DME: 2-year Results (The BEVORDEX Study). *Ophthalmology*. 2016 ; 123(6):1399–401
19. Maturi RK, Bleau L, Saunders J, Mubasher M, Stewart MW. A 12 month, single –masked, randomized controlled study of eyes with persistent diabetic macular edema after multiple anti-VEGF injections to assess the efficacy of the dexamethasone-delayed delivery system as an adjunct to bevacizumab monotherapy. *Retina* 2015; 35(8):1604–14.
20. Totan Y, Guler E, Guragac FB. Dexamethasone intravitreal implant for chronic diabetic macular edema resistant to intravitreal bevacizumab treatment. *Curr Eye Res* 2016; 41(1):107–13.
21. Cerman E, Ozcelik Kose A, Sahin O. The Results of a 12 Month Follow-up of an Intravitreal Dexamethasone Implantation in Persistent Diabetic Macular Edema. *J Retina Vitreus* 2016; 24:218–22.
22. Callanan DG, Loewenstein A, Patel SS, Massin P, Corcóstegui B, Li X, Jiao J, Hashad Y, Whitcup SM. A multicenter, 12-month randomized study comparing dexamethasone intravitreal implant with ranibizumab in patients with diabetic macular edema. *Graefes Arch Clin Exp Ophthalmol* 2017; 255:463–73.
23. Haller JA, Bandello F, Belfort Jr. R, et al. Dexamethasone intravitreal implant in patients with macular edema related to branch or central retinal vein occlusion: twelve-month study results. *Ophthalmology* 2011; 118:2453–60.
24. Mitchell P, Massin P, Bressler S, Coon CD, Petrillo J, Ferreira A, Bressler NM. Three-year patient-reported visual function outcomes in diabetic macular edema managed with ranibizumab: the RESTORE extension study. *Curr Med Res Opin*. 2015; 31(11):1967–75.
25. Elman MJ, Ayala A, Bressler NM, Browning D, Flaxel CJ, Glassman AR, Jampol LM, Stone TW. Intravitreal Ranibizumab for diabetic macular edema with prompt versus deferred laser treatment: 5-year randomized trial results. *Ophthalmology*. 2015; 122(2):375–81.