

# Correlation between Optical Coherence Tomography and Multifocal Electroretinogram Findings in Patients with Central Serous Chorioretinopathy

## Santral Seröz Koryoretinopati Hastalarında Optik Koherens Tomografi ve Multifokal Elektoretinografi Bulgularının Korelasyonu

Metin ÜNLÜ<sup>1</sup>, Ayşe ÖNER<sup>2</sup>, Hekmatullah HEKMAT<sup>3</sup>, Duygu GÜLMEZ SEVİM<sup>4</sup>, Çağatay KARACA<sup>1</sup>, Galip Ertuğrul MİRZA<sup>2</sup>

### ABSTRACT

**Purpose:** To evaluate optical coherence tomography (OCT) and multifocal electroretinogram (mfERG) findings in patients with central serous chorioretinopathy (CSC)

**Methods:** Sixty-two eyes of 31 patients with unilateral treatment naive CSC were included in the study. All subjects underwent complete ophthalmologic examination including best-corrected visual acuity (BCVA), subfoveal and parafoveal choroidal thickness (CT), central foveal thickness (CFT), macular volumes with OCT, and also mfERG responses. Correlation analyses were performed between BCVA, OCT parameters, and mfERG responses.

**Results:** There was significant increase in subfoveal and parafoveal CT in both affected and fellow eyes of CSC compared to healthy subjects. There was significant decrease in the N1, P1, and N2 amplitudes and increase in N1 implicit times for all rings in both affected and fellow eyes of CSC patients compared to control subjects. Correlation analysis revealed that BCVA was significantly correlated with N1, P1, and N2 amplitudes for Ring 1 ( $p<0.05$ ). No significant correlations between BCVA and various OCT parameters were found.

**Conclusion:** Our study showed significant correlations between BCVA (logMAR) and mfERG amplitudes in CSC patients. Furthermore, no significant correlations between BCVA and various OCT parameters were found. Our findings point out that mfERG and OCT could both serve as noninvasive tools for functional and anatomical assessments of CSC patients.

**Key words:** central serous chorioretinopathy, multifocal electroretinogram, optical coherence tomography.

### ÖZ

**Amaç:** Santral seröz koryoretinopati (SSKR) hastalarının optik koherens tomografi (OKT) ve multifokal elektoretinografi (mfERG) bulgularının değerlendirmek.

**Yöntem:** Tek taraflı daha önce tedavi almamış 31 SSKR hastasının 62 gözü çalışmaya dahil edildi. Hastaların tamamına ayrıntılı oftalmolojik muayene ile birlikte en iyi düzeltilmiş görme keskinliği (EİDGK), OKT ile subfoveal ve parafoveal koroid kalınlığı (KK), santral fovea kalınlığı (SFK), makula volümü ölçümleri yapıldı ve ayrıca mfERG cevapları analiz edildi. Korelasyon analizi ile EİDGK, OKT parametreleri ve mfERG cevapları değerlendirildi.

**Bulgular:** Sağlıklı bireyler ile karşılaştırıldığında SSKR hastalarının hem etkilenen gözleri hem de diğer gözlerinde subfoveal ve parafoveal KK değerlerinde anlamlı artış vardı. Sağlıklı bireyler ile karşılaştırıldığında SSKR hastalarının hem etkilenen gözleri hem de diğer gözlerinde tüm halkalarda N1, P1 ve N2 amplitüdlerinde azalma ve N1 iletim zamanında uzama görüldü. Korelasyon analizinde EİDGK değerleri ile mfERG 1. halka N1 dalga amplitüdüleri ( $p<0,05$ ) arasında anlamlı korelasyon bulundu. EİDGK ile OKT parametreleri arasında anlamlı korelasyon bulunmadı.

**Sonuç:** Çalışmamızda SSKR hastalarında EİDGK değerleri ile mfERG amplitüdüleri arasında anlamlı korelasyon bulundu. Ayrıca EİDGK ile farklı OKT parametreleri arasında anlamlı korelasyon bulunmadı. SSKR hastalarının anatomik ve fonksiyonel değerlendirilmesinde mfERG ve OCT birbirlerini tamamlayıcı invaziv olmayan tetkikler olarak kullanılabilir.

**Anahtar Kelimeler:** Santral seröz koryoretinopati, multifokal elektoretinografi, optik koherens tomografi.

1- Yrd. Doç. Dr., Erciyes Üniversitesi, Göz Hastalıkları ABD, Kayseri, Türkiye

2- Prof. Dr., Erciyes Üniversitesi, Göz Hastalıkları ABD, Kayseri, Türkiye

3- Asist. Dr., Erciyes Üniversitesi, Göz Hastalıkları ABD, Kayseri, Türkiye

4- Uz. Dr., Erciyes Üniversitesi, Göz Hastalıkları ABD, Kayseri, Türkiye

Geliş Tarihi - Received: 19.12.2017

Kabul Tarihi - Accepted: 22.03.2018

Ret-Vit 2019; 28: 37-43

Yazışma Adresi / Correspondence Address:

Metin ÜNLÜ

Erciyes Üniversitesi, Göz Hastalıkları, Kayseri, Türkiye

Phone: +90 352 207 6666

E-mail: drunlumetin@hotmail.com

## INTRODUCTION

Central serous chorioretinopathy (CSC) is characterized by serous retinal detachment and/or pigment epithelial detachment (PED), predominantly affecting the macular area, and usually associated choroidal hyperpermeability, and increased choroidal thickness. Central serous chorioretinopathy generally resolves spontaneously within 2 to 3 months with minimal sequelae, observation without treatment is generally recommended as initial management.<sup>1</sup>

<sup>2</sup> Recurrent or persistent disease can lead to widespread RPE damage, photoreceptor death, and deterioration in vision permanently.<sup>2</sup>

Several reports have investigated the relationship between retinal outer structures and visual acuity in eyes with CSC. A decrease in outer nuclear thickness<sup>3-5</sup> or disruption of the external limiting membrane (ELM) and the photoreceptor inner and outer segment (IS/OS) junction,<sup>6, 7</sup> recently called an ellipsoid zone,<sup>8</sup> has been shown to correlate with visual acuity loss. Intraretinal hyperreflective foci or hyperreflective dots have been described in patients with active CSC. The hyperreflective foci were thought to possibly serve as accumulations of proteins or activated microglia or macrophages.<sup>9</sup>

Previous studies have reported that functional evaluation of CSC can be achieved with mfERG. Decreased mfERG response amplitudes with delayed latencies in corresponding areas of the neurosensory retinal detachment has been demonstrated in recent studies.<sup>10-17</sup> However there are only few studies which attempted to evaluate the correlation between functional and structural changes in CSC patients.<sup>16, 18</sup>

In this study we aim to assess the correlation between the functional mfERG responses, structural chorioidal and retinal OCT findings in eyes with chronic CSC.

## METHODS

This cross-sectional, non-randomized, comparative study was carried out at the Department of Ophthalmology, University Hospital of Erciyes, from January to March 2016 after review and receiving approval from the Institutional Review Board of the University Hospital. Signed informed consent was obtained from all the participants.

Patients with unilateral, treatment naive CSC of less than 6 months duration and age- and sex- matched healthy controls were included in the study.

Exclusion criteria were a history of previous eye surgery or trauma, retinal pathology other than CSC (macular oedema, epiretinal membrane, diabetic retinopathy, wet or dry age-related macular degeneration), and media opacity. All patients and healthy controls with a refractive error of greater than  $\pm 6.00$  diopters were excluded because

pathologic myopia/hypermetropia may have affected the analysis of the choroid. There was not significant difference between CSC patients and healthy controls with respect to axial length and refraction.

All measurements were made between 10 AM and 2 PM to limit the potential confounding influence of diurnal variations on OCT. Patients and healthy controls were asked to not consume topical drops (mydriatics) and alcoholic or caffeinated drinks for at least 12 hours before having their measurements taken.

Charts of the participants who had a complete ophthalmologic examination including BCVA, central foveal thickness (CFT), and choroidal thickness (CT) measurements (Spectralis OCT; Heidelberg Engineering, Heidelberg, Germany) and the CSC patients' mf-ERG recordings (Vision Monitor, Monpack 3, Metrovision, France) were used in the study.

Best-corrected visual acuity recorded in Snellen equivalents was converted into the logarithm of the minimum angle of resolution (logMAR) for the statistical analysis.

## OCT imaging

Imaging was performed after standard pupillary dilation using tropicamide 0.5% drops with the Spectralis (Heidelberg Engineering, Heidelberg, Germany). A 30°x20° 97-sections SD-OCT macular volume, a 30° enhanced-depth imaging (EDI) SD-OCT horizontal scan through the fovea the "automatic real time" averaging set at the maximal value of 100 images, a 30°x30° fundus infrared reflectance were acquired.

All scans were performed with support of the eye tracking system. Average thicknesses were calculated for macular retinal nerve fiber layer (mRNFL), ganglion cell layer (GCL), inner plexiform layer (IPL), inner nuclear layer (INL), outer plexiform layer (OPL), outer nuclear layer (ONL), inner and outer segments of the photoreceptors (PR) and retinal pigment epithelium (RPE).

Macular volumes were quantified using the software of the manufacturer based on the ETDRS protocol. Three retinal volumes were centered on the foveola with radii of 0.5, 1.0 mm, and 1.5 mm. Macular volumes were divided into two regions as inner macular and outer macular. Inner macular volume was defined as the average of five measurements at foveal center and 500  $\mu$ m away from the nasal, temporal, superior, and inferior directions of the foveal center. Outer macular volume was defined as the average of four measurements at 1.500  $\mu$ m away from the nasal, temporal, superior, and inferior directions of foveal center.

Choroidal thickness (CT) was measured manually by the same observer on enhanced-depth imaging scans as the axial distance from the RPE to the outer choroid/sclera

interface at 7 different points (from the central subfoveal point, and 500, 1.000, and 1.500  $\mu\text{m}$  away from the foveal center at nasal and temporal quadrants).<sup>19</sup> Submacular CT measurements were divided into two regions as subfoveal and parafoveal. Subfoveal CT was defined as the average of 3 CT measurements at foveal center and 500  $\mu\text{m}$  away from the nasal and temporal directions of the foveal center. Parafoveal CT was defined as the average of 4 CT measurements at 1.000  $\mu\text{m}$  and 1.500  $\mu\text{m}$  away from the nasal and temporal directions of foveal center.

The central subretinal fluid (SRF) thickness was defined as the axial distance between the RPE and the outer aspect of photoreceptor outer segments. the vertical and horizontal SRF diameters were measured at the maximum width of the SRF in the vertical and horizontal OCT scans.

### Multifocal electroretinography

Multifocal ERG (Vision Monitor, Monpack 3, Metrovision, France) was recorded according to the ISCEV guidelines.<sup>20</sup> Patients were light adapted for at least 15 minutes in room light, with fully dilated pupils. A liquid crystal display screen was used to produce 61 scaled hexagonal stimulus patterns (30-degree horizontal and 24-degree vertical field) with central fixation point. Luminance of bright and dark hexagons was kept at 100  $\text{cd}/\text{m}^2$  and  $<1 \text{ cd}/\text{m}^2$ , respectively. The recording was performed monocularly using contact lens electrodes after anaesthetizing the cornea with topical 1% proparacaine drops, with refractive correction prescribed for near vision. The right eye was tested first, followed by the left eye, each with fresh disposable corneal electrodes. The stimulus frequency was set at 17 Hz and overall duration of pseudo-random stimulation was 5 minutes.

### Analysis of mfERG

The first-order mfERG responses were analyzed using color maps of amplitudes given as density and implicit times of N1, P1 and N2 wave peaks. The typical waveform of the mfERG response is a biphasic wave with an initial negative deflection followed by a positive peak. There is usually a second negative deflection after the positive peak. These three peaks are called N1, P1, and N2, respectively. The average responses were over a group of up to five rings from zero to 25 degrees of eccentricity relative to fixation. The analysis develops a histogram for each of the extended zones indicating the average amplitude of the N1, P1, N2 peaks.

### Statistical Analysis

Data were analyzed using SPSS software (SPSS 18.0, SPSS Inc., Chicago, IL). Descriptive statistics were performed for all parameters. Data were tested for normal distribution using the Kolmogorov-Smirnov test. Spearman correlation was used to evaluate the correlations between BCVA, OCT parameters, and mfERG findings. P-values  $<0.05$  were considered significant for statistical test.

## RESULTS

A total of 31 CSC (62 eyes) patients were compared to 30 healthy (30 eyes) controls. Demographic and clinical characteristics of the CSC patients and healthy controls are shown in Table 1. There were no differences between participants in the CSC patients and control groups with respect to age or gender. Best-corrected visual acuity (logMAR) scores were significantly poorer in affected eyes of CSC patients compared to controls ( $p=0.01$ ). The mean duration of symptoms in CSC subjects was  $4.4 \pm 1.1$  months. The mean vertical and horizontal SRF thicknesses were

**Table 1.** Clinical characteristics and OCT parameters of study subject and healthy control.

	CSC group Affected eye (n=31)	CSC group Fellow eye (n=31)	Control group (n=30)	P value
Age (y. mean $\pm$ SD)	48.78 $\pm$ 8.79	48.78 $\pm$ 8.79	49.12 $\pm$ 9.23	0.4
Duration of symptoms. months	5.4 $\pm$ 2.1	-	-	-
BCVA (logMAR)	0.49 $\pm$ 0.39	0.15 $\pm$ 0.28	0.10 $\pm$ 0.14	*0.01
Central foveal thickness (CFT). $\mu\text{m}$	338.40 $\pm$ 119.34	229.82 $\pm$ 38.60	225.42 $\pm$ 42.30	* $<0.0001$
Subfoveal CT. $\mu\text{m}$	343.80 $\pm$ 94.44	346.81 $\pm$ 144.58	331.42 $\pm$ 96.12	*0.02
Parafoveal CT. $\mu\text{m}$	237.93 $\pm$ 137.25	242.25 $\pm$ 175.69	228.83 $\pm$ 85.76	*0.02
Inner macular volume. $\text{mm}^3$	2.44 $\pm$ 0.39	2.36 $\pm$ 0.14	2.34 $\pm$ 0.34	0.4
Outer Macular volume. $\text{mm}^3$	6.58 $\pm$ 1.09	6.73 $\pm$ 1.12	6.68 $\pm$ 1.06	0.3
Vertical diameter of SRF. $\mu\text{m}$	156.18 $\pm$ 113.76	19.00 $\pm$ 7.37	-	* $<0.0001$
Horizontal diameter of SRF. $\mu\text{m}$	1998 $\pm$ 1082	179.39 $\pm$ 65.02	-	* $<0.0001$

SD: standard deviation. BCVA: Best corrected visual acuity. IRL: Inner retinal layer. ORL: Outer retinal layer. CT: Choroid thickness. SRF: Subretinal fluid. \*P value  $<0.05$  was considered statistically significant.

significantly higher in CSC patients versus healthy subjects. The central foveal thickness was significantly higher in affected eyes of CSC (338.40  $\mu\text{m}$ ) compared to fellow eyes of CSC (229.82  $\mu\text{m}$ ) and healthy control (225.42  $\mu\text{m}$ ) ( $p < 0.001$ ).

There was significant increase in subfoveal and parafoveal CT in both affected and fellow eyes of CSC compared

to healthy subjects ( $p < 0.05$ ) (Table 1). There was not significant difference in inner and outer macular volumes between CSC patients and healthy controls.

The mean mfERG N1, P1, and N2 amplitudes are presented in Table 2. There was significant decrease in the N1, P1, and N2 amplitudes for all rings in both affected and fellow eyes of CSC patients compared to control subjects ( $p <$

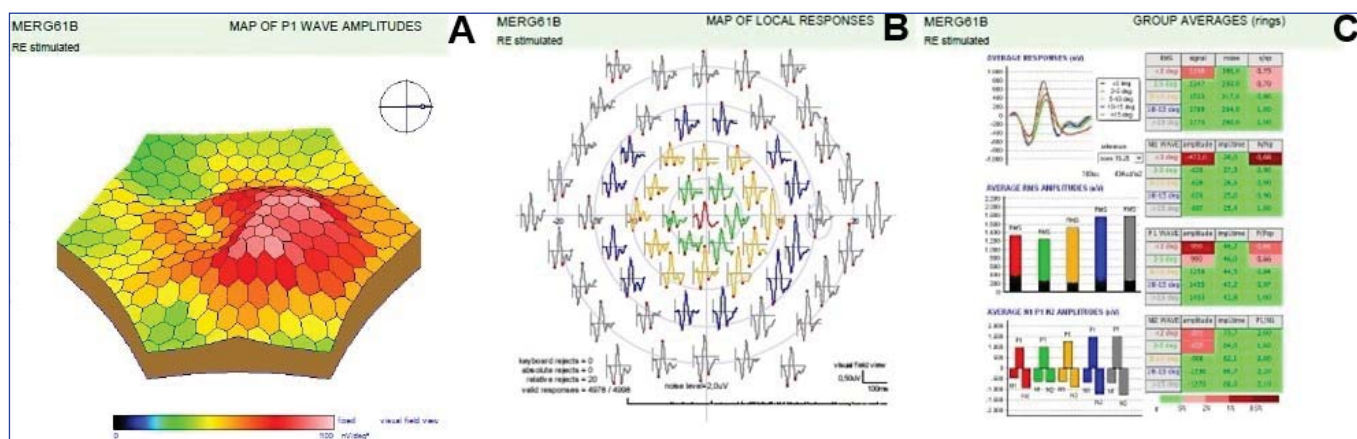
**Table 2.** Comparison of mfERG parameters between central serous chorioretinopathy and control subjects.

mfERG parameters	CSC group Affected eye (n=31)	CSC group Fellow eye eye (n=31)	Control group (n=30)	P value
<b>Amplitude N1 (Nv/deg<sup>2</sup>)</b>				
Ring 1 (<2°)	-583.12±337.5	-891.40± 415.98	-1521.74±315.78	*<0.0001
Ring 2 (2-5°)	-503.26±226.20	-558.03±207.64	-801.97±145.97	*<0.0001
Ring 3 (5-10°)	-436.62±342.01	-458.92±274.27	-706.88±103.66	*<0.0001
Ring 4 (10-15°)	-518.03±202.79	-546.28±138.73	-677.42±104.97	*<0.0001
Ring 5 (>15°)	-554.25±148.91	-561.00±137.88	-610.45±529.78	*<0.0001
<b>Amplitude P1 (Nv/deg<sup>2</sup>)</b>				
Ring 1 (<2°)	999.90±527.32	1545.35±684.25	2516.57±546.64	*<0.0001
Ring 2 (2-5°)	965.50±362.78	1122.21±340.48	1542.60±327.30	*<0.0001
Ring 3 (5-10°)	1047.31±310.09	1063.96±284.11	1448.25±193.67	*<0.0001
Ring 4 (10-15°)	1111.15±280.03	1133.00±298.64	1436.22±208.51	*<0.0001
Ring 5 (>15°)	1261.46±312.61	1262.28±349.68	1458.68±686.02	*<0.0001
<b>Amplitude N2 (Nv/deg<sup>2</sup>)</b>				
Ring 1 (<2°)	-799.31±482.28	-1374.25±838.30	-2327.14±575.09	*<0.0001
Ring 2 (2-5°)	-749.21±366.60	-942.25±336.87	-1220.14±674.08	*<0.0001
Ring 3 (5-10°)	-861.65±297.36	-931.46±284.88	-1159.37±482.14	*<0.0001
Ring 4 (10-15°)	-1024.93±274.92	-1037.46±294.39	-1306.25±225.24	*<0.0001
Ring 5 (>15°)	-1029.93±278.46	-1173.85±374.14	-1449.37±252.81	*<0.0001
<b>Implicit Time N1 (ms)</b>				
Ring 1 (<2°)	27.63±5.77	27.38±2.58	26.88±1.66	*0.004
Ring 2 (2-5°)	27.32±1.34	26.74±1.63	26.28±1.30	*0.012
Ring 3 (5-10°)	26.52±1.15	25.93±1.49	25.41±1.57	*0.008
Ring 4 (10-15°)	26.12±1.11	25.97±1.15	25.31±1.19	*0.009
Ring 5 (>15°)	26.13±1.20	25.81±1.05	25.90±3.87	*0.04
<b>Implicit Time P1 (ms)</b>				
Ring 1 (<2°)	49.50±8.94	48.70±3.39	46.56±2.61	0.09
Ring 2 (2-5°)	46.16±1.58	45.74±1.86	45.56±1.46	0.2
Ring 3 (5-10°)	44.66±1.33	44.15±1.32	43.83±1.37	*0.02
Ring 4 (10-15°)	43.97±1.24	43.52±1.37	43.22±1.31	0.05
Ring 5 (>15°)	43.86±1.37	43.78±1.21	43.45±4.02	0.3
<b>Implicit Time N2 (ms)</b>				
Ring 1 (<2°)	71.23±21.76	70.32±19.33	66.12±3.56	0.05
Ring 2 (2-5°)	65.31±13.67	63.25±13.07	64.57±1.98	0.3
Ring 3 (5-10°)	62.24±12.03	61.92±1.59	61.26±1.51	0.2
Ring 4 (10-15°)	61.73±1.35	61.15±1.64	61.05±1.58	0.1
Ring 5 (>15°)	61.29±1.55	60.88±1.46	60.78±1.54	0.4
mfERG: multifocal electroretinography. *P value < 0.05 was considered statistically significant.				

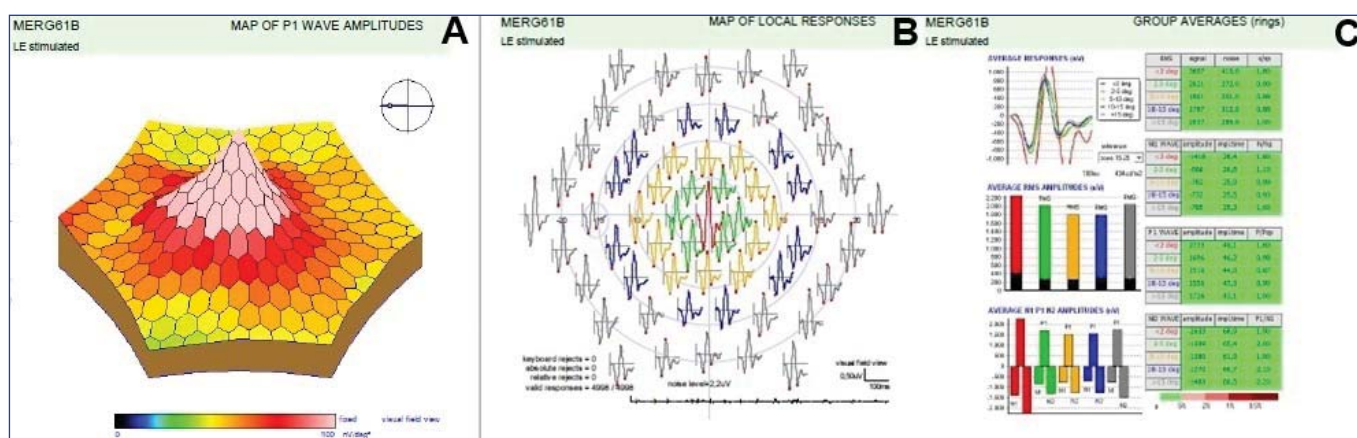


0.001) (Figure 1-3). There was significant decrease in N1, P1, and N2 amplitudes only for Ring 1 in affected eyes of CSC patients versus fellow eyes. There was also significant increase in N1 implicit times for all of five rings in both

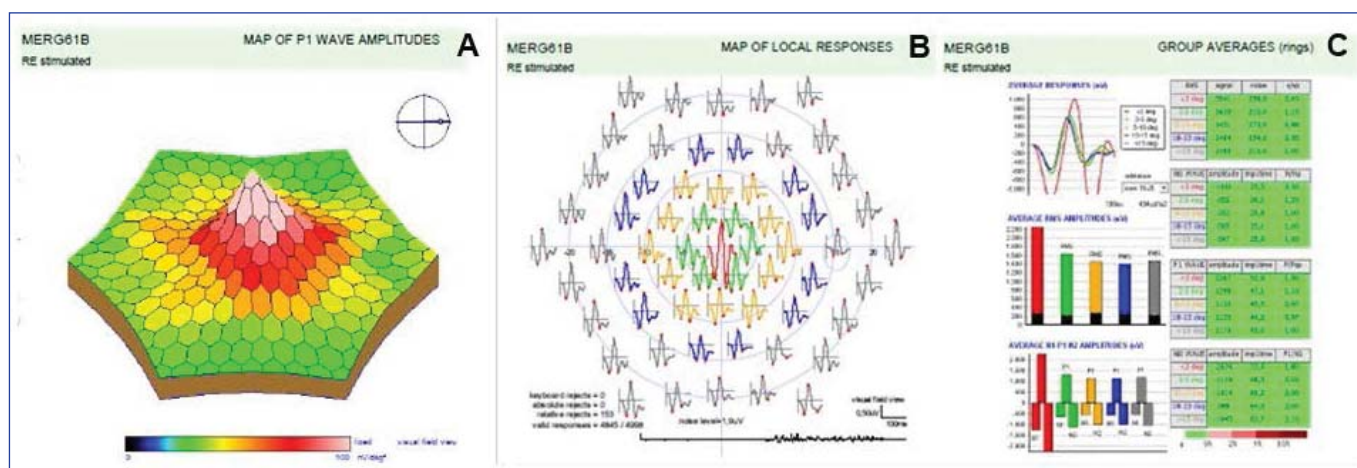
affected and fellow eyes of CSC patients compared to healthy controls ( $p < 0.05$ ). There was no difference in the mean N2 implicit times for all rings between CSC and control subjects. The mean mfERG N1, P1, and N2 implicit



**Figure 1.** Example of mfERG recordings and macular OCT scan of a CSC patient's affected eye. (A) Response density three-dimensional plot at the central macula. (B) first-order trace array. (C) average reduced amplitudes and increased implicit times of rings.



**Figure 2.** Example of mfERG recordings and macular OCT scan of a CSC patient's fellow eye. (A) Response density three-dimensional plot at the central macula. (B) first-order trace array. (C) average reduced amplitudes and increased implicit times of rings.



**Figure 3.** Example of mfERG recordings and macular OCT scan of a normal subject. (A) Response density three-dimensional plot at the central macula. (B) first-order trace array. (C) average amplitudes and implicit times of rings.

times for all rings were the same for affected and fellow eyes of CSC patients.

Spearman correlation analyses was performed to evaluate the association between BCVA, OCT parameters and mfERG findings. The BCVA was significantly correlated with N1, P1, and N2 amplitudes for Ring 1 ( $r = 0.808$ ;  $p = 0.003$ ,  $r = -0.545$ ;  $p = 0.03$ ,  $r = -0.551$ ;  $p = 0.03$ , respectively). No significant correlations between BCVA and OCT parameters (CFT, subfoveal and parafoveal CT, vertical and horizontal diameters of SRF, inner and outer macular volumes) were found. In addition, we found moderate correlations between inner macular volumes and N1, P1, and N2 implicit times of Rings 4 and 5. The horizontal diameter of SRF was moderately correlated with P1 implicit times of Ring 5 and N2 implicit times of Ring 2.

## DISCUSSION

Our study revealed significant correlations between BCVA (logMAR) and mfERG amplitudes in CSC patients. Furthermore, no significant correlations between BCVA and OCT parameters (CFT, subfoveal and parafoveal CT, vertical and horizontal diameters of SRF, inner and outer macular volumes) were found.

The multifocal ERG (mfERG) was established to contribute a topographical assessment of retinal electrophysiological response.<sup>20</sup> The principal scientific use of the mfERG is to recognize spatial variations in mfERG activities that pinpoint retinal damage to distinct zones of retina: the macula, paramacula, or distinct peripheral regions<sup>20</sup>. Decreased mfERG response amplitudes with delayed latencies in CSC patients has been demonstrated but only few attempted to assess the correlation between functional and structural changes.<sup>16, 18</sup> Moschos et al. evaluated mfERG and OCT findings in unilateral CSC patients at presentation and after resolution of disease. They performed automatic central retinal thickness measurement using the OCT software and did not evaluate correlation between the OCT and mfERG parameters. In another OCT study manual measurements were performed for various OCT parameters, including central retinal thickness, central SRF thickness and diameter of SRF, in CSC patients.<sup>18</sup> They concluded that they could perform more accurate thickness measurements and enable to correlate mfERG and the OCT parameters by manual OCT measurement method. We also performed manual OCT measurements according to their suggestions.

Choroidal hyperpermeability and choroidal thickening play crucial role in the pathogenesis of CSC, but their relationship is still controversy. We found the statistically significant increase in subfoveal and parafoveal CT in both affected and fellow eyes of CSC compared to healthy subjects. Choroidal hyperpermeability has been reported in >90% of affected eyes of patients with CSC and 62–73% of unaffected fellow

eyes in the literature.<sup>21-23</sup> Maruko et al reported that the choroid was thicker in fellow eyes of patients with CSC with choroidal hyperpermeability than those without choroidal hyperpermeability.<sup>22</sup> Kim et al founded that choroidal vascular dilatation was present in 70% of CSC eyes and 60% of unaffected fellow eyes.<sup>21</sup> They stated that choroidal dilatation and hyperpermeability may be different phases of the disease.<sup>21</sup> There was significant decrease in the N1, P1, and N2 amplitudes for all rings in both affected and fellow eyes of CSC patients compared to control subjects. Although patients did not suffer decreased vision from their fellow eyes, both eyes had decreased mfERG amplitudes.

In our study, we found significant correlations between BCVA (logMAR) and mfERG amplitudes in CSC patients. However, our results revealed that BCVA did not correlate with any of the OCT parameters. These results are compatible with previous study of Yip et al that evaluated the correlation between functional and anatomical findings in CSC patients.<sup>18</sup>

We also found that there was no significant correlation between mfERG amplitudes and OCT parameters. The lack of correlation between mfERG amplitudes and OCT parameters proposed that the amount of SRF did not appear to have noticeable impact on the mfERG amplitudes. This might be due to other factors which can influence macular function including chronicity of CSC, the content of SRF, and any preceding photoreceptor loss.<sup>18</sup>

Furhermore our study revealed significant correlations between N1, P1, and N2 implicit times of the paracentral rings (Rings 4 and 5) with the inner macular volumes. In addition, the horizontal diameter of SRF was also found moderately significantly correlated with P1 latencies of Ring 5 and N2 latencies of Ring 2. Yip et al found significant correlation between mfERG N1 and P1 latencies of the paracentral rings and the central SRF thickness, diameters of the SRF, and macular volume. Their findings suggested that delayed electrical responses from the photoreceptors and the inner retinal layers are in proportional to the amount of SRF in CSC.<sup>18</sup>

Our study had several limitations, particularly due to the small number of CSC patients and cross-sectional assessment of OCT and mfERG findings, a longitudinal study should be more proper for evaluating the correlations with disease severity and duration.

In conclusion, our study showed significant correlations between BCVA (logMAR) and mfERG amplitudes in CSC patients. Furthermore, no significant correlations between BCVA and various OCT parameters were found. Therefore, mfERG findings seem a more sensitive prognostic factor for visual acuity compared with OCT. Our findings point out that mfERG and OCT could both serve as noninvasive tools for functional and anatomical assessments of CSC patients.

## REFERENCES / KAYNAKLAR

- Nicholson B, Noble J, Forooghian F, Meyerle C. Central serous chorioretinopathy: update on pathophysiology and treatment. *Surv Ophthalmol* 2013; 58:103-26.
- Daruich A, Matet A, Dirani A, Bousquet E, Zhao M, Farman N, Jaisser F, Behar-Cohen F. Central serous chorioretinopathy: Recent findings and new physiopathology hypothesis. *Prog Retin Eye Res* 2015; 48:82-118.
- Ojima Y, Hangai M, Sasahara M, Gotoh N, Inoue R, Yasuno Y, Makita S, Yatagai T, Tsujikawa A, Yoshimura N. Three-dimensional imaging of the foveal photoreceptor layer in central serous chorioretinopathy using high-speed optical coherence tomography. *Ophthalmology* 2007; 114:2197-207.
- Matsumoto H, Sato T, Kishi S. Outer nuclear layer thickness at the fovea determines visual outcomes in resolved central serous chorioretinopathy. *Am J Ophthalmol* 2009; 148:105-10 e1.
- Piccolino FC, de la Longrais RR, Ravera G, Eandi CM, Ventre L, Abdollahi A, Manea M. The foveal photoreceptor layer and visual acuity loss in central serous chorioretinopathy. *Am J Ophthalmol* 2005; 139:87-99.
- Yalcinbayir O, Gelisken O, Akova-Budak B, Ozkaya G, Gorkem Cevik S, Yucel AA. Correlation of spectral domain optical coherence tomography findings and visual acuity in central serous chorioretinopathy. *Retina* 2014; 34:705-12.
- Hasegawa T, Okamoto M, Masuda N, Ueda T, Ogata N. Relationship between foveal microstructures and visual outcomes in eyes with resolved central serous chorioretinopathy. *Graefes Arch Clin Exp Ophthalmol* 2015; 253:343-50.
- Spaide RF, Curcio CA. Anatomical correlates to the bands seen in the outer retina by optical coherence tomography: literature review and model. *Retina* 2011; 31:1609-19.
- Kon Y, Iida T, Maruko I, Saito M. The optical coherence tomography-ophthalmoscope for examination of central serous chorioretinopathy with precipitates. *Retina* 2008; 28:864-9.
- Lai TY, Lai RY, Ngai JW, Chan WM, Li H, Lam DS. First and second-order kernel multifocal electroretinography abnormalities in acute central serous chorioretinopathy. *Doc Ophthalmol* 2008; 116:29-40.
- Huang S, Wu D, Jiang F, Wu L, Liang J, Luo G, Wen F, Ma J. The multifocal electroretinogram in central serous chorioretinopathy. *Ophthalmic Physiol Opt* 2002; 22:244-7.
- Vajaranant TS, Szlyk JP, Fishman GA, Gieser JP, Seiple W. Localized retinal dysfunction in central serous chorioretinopathy as measured using the multifocal electroretinogram. *Ophthalmology* 2002; 109:1243-50.
- Zhang W, Zhao K. Multifocal electroretinography in central serous chorio-retinopathy and assessment of the reproducibility of the multifocal electroretinography. *Doc Ophthalmol* 2003; 106:209-13.
- Chappelov AV, Marmor MF. Multifocal electroretinogram abnormalities persist following resolution of central serous chorioretinopathy. *Arch Ophthalmol* 2000; 118:1211-5.
- Marmor MF, Tan F. Central serous chorioretinopathy: bilateral multifocal electroretinographic abnormalities. *Arch Ophthalmol* 1999; 117:184-8.
- Moschos M, Brouzas D, Koutsandrea C, Stefanos B, Loukianou H, Papantonis F, Moschos M. Assessment of central serous chorioretinopathy by optical coherence tomography and multifocal electroretinography. *Ophthalmologica* 2007; 221:292-8.
- Suzuki K, Hasegawa S, Usui T, Ichibe M, Takada R, Takagi M, Abe H. Multifocal Electroretinogram in Central Serous Chorioretinopathy. *Jpn J Ophthalmol* 2000; 44:571.
- Yip YW, Ngai JW, Fok AC, Lai RY, Li H, Lam DS, Lai TY. Correlation between functional and anatomical assessments by multifocal electroretinography and optical coherence tomography in central serous chorioretinopathy. *Doc Ophthalmol* 2010; 120:193-200.
- Vural E, Acar U, Sevinc MK, Erdurmus M, Kucuk B, Aykas S, Sobaci G. Choroidal Thickness in Patients with Stargardt Disease. *Retina* 2017.
- Hood DC, Bach M, Brigell M, Keating D, Kondo M, Lyons JS, Marmor MF, McCulloch DL, Palmowski-Wolfe AM, International Society For Clinical Electrophysiology of V. ISCEV standard for clinical multifocal electroretinography (mfERG) (2011 edition). *Doc Ophthalmol* 2012; 124:1-13.
- Kim YT, Kang SW, Bai KH. Choroidal thickness in both eyes of patients with unilaterally active central serous chorioretinopathy. *Eye (Lond)* 2011; 25:1635-40.
- Maruko I, Iida T, Sugano Y, Ojima A, Sekiryu T. Subfoveal choroidal thickness in fellow eyes of patients with central serous chorioretinopathy. *Retina* 2011; 31:1603-8.
- Ersoz MG, Karacorlu M, Arf S, Hocaoglu M, Sayman Muslubas I. Pachychoroid pigment epitheliopathy in fellow eyes of patients with unilateral central serous chorioretinopathy. *Br J Ophthalmol* 2017.