

Relja Zivojnovic Award Lecture: Endophthalmitis Management Using Small Gauge Vitrectomy, Silicone Oil, and Alternative Antimicrobials

Relja Zivojnovic Onur Dersi: Endoptalmi Tedavisinde Küçük Kesili Vitrektomi, Silikon Yağı ve Alternatif Antimikrobiyotikler

Harry W. FLYNN Jr.,¹ Nidhi Batra RELHAN,² Stephen G. SCHWARTZ,³ Andrzej GRZYBOWSKI⁴

ABSTRACT

Endophthalmitis is relatively uncommon in clinical practice but is especially challenging for vitreoretinal specialists. Prior to the widespread use of pars plana vitrectomy, patients with endophthalmitis were often managed by cornea specialists or by comprehensive ophthalmologists. The Endophthalmitis Vitrectomy Study (EVS) showed the clear-cut role for pars plana vitrectomy for patients with more advanced infection following cataract surgery or secondary intraocular lens implantation.

Key Words: Small gauge vitrectomy, silicone oil, antimicrobials.

ÖZ

Endoftalmi, klinik pratiğimizde oldukça nadirdir fakat özellikle vitreoretimal cerrahların gözün gerdikleri bir durumdur. Pars Plana vitrektomide yaygın olarak kullanımından önce sıklıkla kornea uzmanları veya genel oftalmologlar tarafından tedavi edilirdi. Endoftalmi vitrektomi çalışma grubu, katarakt ameliyatı veya sekonder introoküler lens implantasyonundan sonra gelişen çok ciddi enfeksiyonların tedavisinde PPV'nin rolünü açık bir şekilde ortaya koymuştur.

Anahtar Sözcükler: Küçük kesili vitrektomi, silikon yağı, antimikrobial ajanlar.

Relja Zivojnovic was an outstanding vitreoretinal surgeon and innovator in our field. Born in Austria in 1931, he grew up in Yugoslavia. After graduation from high school in 1949, he had preliminary education and then medical school. He briefly trained in general surgery before entering the field of ophthalmology. His mother was an ophthalmologist and she influenced him to enter this field. After residency in Rotterdam, in the late 1970s, after several visits to work with John Scott in Cambridge England, Dr. Zivojnovic introduced silicone oil into his surgery for patients with complex vitreoretinal disease. He eventually returned to Rotterdam to become one of the world's most recognized and respected vitreo-

retinal surgeons. His willingness to take the most complex patients earned him the respect and admiration of his colleagues. His teaching and video documentation of surgical techniques was a great service for all vitreoretinal surgeons. It is with great admiration that we dedicate this lecture to our friend and mentor Dr. Relja Zivojnovic (Figure 1).

Endophthalmitis is relatively uncommon in clinical practice but is especially challenging for vitreoretinal specialists. Prior to the widespread use of pars plana vitrectomy, patients with endophthalmitis were often managed by cornea specialists or by comprehensive ophthalmologists. The

1- M.D., Department of Ophthalmology, Bascom Palmer Eye Institute, University of Miami Miller School of Medicine, Miami, FL.

2- M.D., MBA, Department of Ophthalmology, Bascom Palmer Eye Institute, University of Miami Miller School of Medicine, Naples, FL.

3- Department of Ophthalmology, Poznań City Hospital, Poznań, Wielkopolska, Poland.

4- M.D., PhD., Department of Ophthalmology, University of Warmia and Mazury, Olsztyn, Warmia and Mazury, Poland.

Geliş Tarihi - Received: 07.09.2017

Kabul Tarihi - Accepted: 08.10.2017

Ret-Vit 2017; 26: 283-288

Yazışma Adresi / Correspondence Address:

Harry W. Flynn Jr.
Bascom Palmer Eye Institute 900 N.W. 17th Street
Miami, FL 33126 USA

Phone: +1 305 326 6118

E-mail: hflynn@med.miami.edu




Figure 1: Dr. Relja Zivojnovic.

Endophthalmitis Vitrectomy Study (EVS) showed the clear-cut role for pars plana vitrectomy for patients with more advanced infection following cataract surgery or secondary intraocular lens implantation.¹ Since the EVS, techniques have evolved from 20-gauge surgery into small gauge sutureless transconjunctival surgery allowing a quicker surgical procedure but generally still requiring use of the operating room.²

Silicone oil is commonly used in the management of complex retinal detachment (RD) associated with proliferative vitreoretinopathy (PVR) or open globe injuries.^{3,4} Silicone oil does not support the growth of microbial organisms and therefore appears to have an increasing role as an adjunct in the management of patients with more advanced endophthalmitis.⁵

Emerging antimicrobial resistance is a worldwide concern.⁶ In the case of vancomycin which is the major antibiotic used for empiric coverage of gram positive infections, resistance is associated with very poor treatment outcomes.⁶ Alternative antibiotic choices will be increasingly important in the future.

The purpose of the current report is to discuss the evolving role of small gauge pars plana vitrectomy, silicone oil, and alternative antimicrobial agents in the management of a spectrum of endophthalmitis categories.

SMALL GAUGE VITRECTOMY

In 1971, Robert Machemer first introduced a closed system to remove vitreous while maintaining intraocular pressure.⁷

Since then, the vitrectomy procedure and instrumentation have undergone major modifications to increase the safety and effectiveness. The evolution of small gauge transconjunctival sutureless pars plana vitrectomy began in 1996 when Chen described the first procedure. Further modification in this approach occurred in 2002 with Fuiji and DeJuan reporting 25-gauge surgery outcomes in a clinical series.⁸ This approach to vitrectomy was widely adapted but was further changed in 2005 by Eckardt who introduced 23-gauge transconjunctival vitrectomy.⁸ The latest innovation is 27-gauge surgery introduced by Oshima in 2010.⁸ Today all of these small gauge vitrectomy options are available to the vitreoretinal surgeons but 27-gauge surgery is especially suited for the core vitrectomy in eyes with endophthalmitis (Figure 2-3).

Small gauge sutureless transconjunctival surgery has advantages over traditional 20-gauge pars plana vitrectomy. These

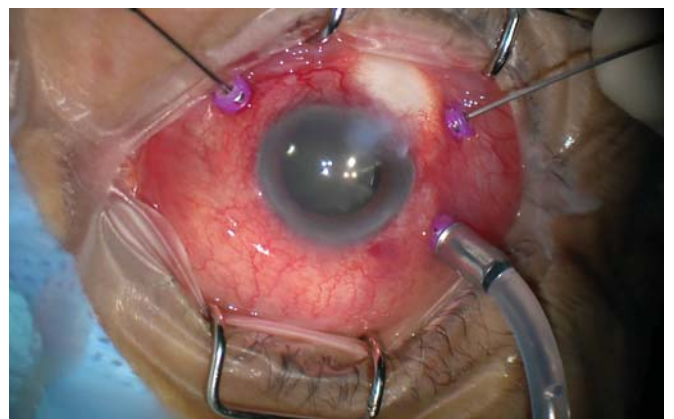


Figure 2: 27-Gauge transconjunctival pars plana vitrectomy is ideal for the management of acute endophthalmitis cases as it remarkably reduces chances of bleeding from marked conjunctival congestion and extremely small sized sclerotomy ports. Furthermore, core vitrectomy is what is required in a case of acute endophthalmitis.

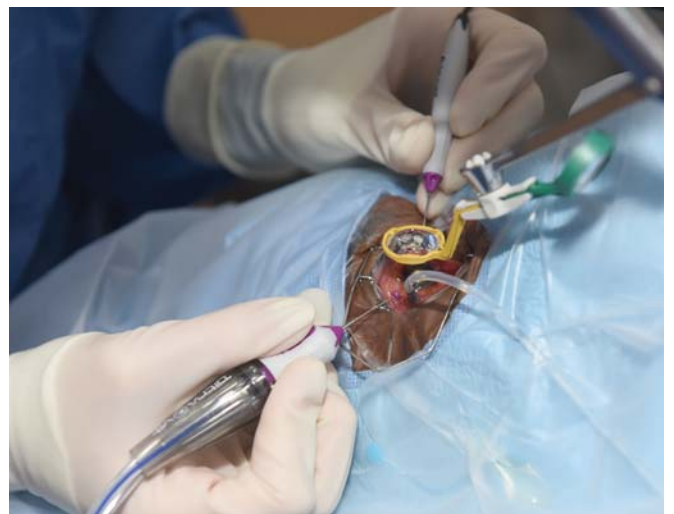

Figure 3: Sideview of hands on transconjunctival pars plana vitrectomy showing BIOM and 27-Gauge cannula in place.

advantages include no need for conjunctival injection (with associated bleeding in inflamed eyes), no sutures, decreased operating time, decreased pain, decreased tissue trauma, and decreased astigmatism from suture placement. The procedure generally is performed under regional anesthesia with monitored anesthesia care. In more recent years, some surgeons have used subconjunctival anesthesia alone for relatively quick vitrectomy procedures such as used in patients with endophthalmitis.

Although the role of pars plana vitrectomy for treatment of postcataract surgery endophthalmitis in the EVS is proven, the value of this modality for other etiologic categories remains controversial. The theoretical advantages of pars plana vitrectomy include debriding of intravitreal infection, removing vitreous opacities and membranes obstructing vision, collecting a relatively large sample of vitreous for culture, and allowing better distribution of injected intravitreal antimicrobial agents.

The outcomes of the EVS were reported in 1995 and have been broadly adopted into clinical practice. The EVS reported that in endophthalmitis patients whose visual acuity when initially examined was hand motion or better, there was no difference in visual acuity outcomes whether or not immediate pars plana vitrectomy was performed.¹ However, in the subgroup of patients whose visual acuity was only light perception, there was a 3-fold increase in the frequency of achieving 20/40 or better visual acuity, an approximately 2-fold chance of achieving 20/100 or better visual acuity and a 50% decrease in the frequency of severe visual loss to worse than 5/200 visual acuity. The EVS did not state that pars plana vitrectomy should not be performed in eyes with hand motions or better visual acuity but rather it implied that a TAP and inject procedure was quicker and easier than going to the operating room for pars plana vitrectomy.

For patients with hand motions or better visual acuity treated with a TAP and injection procedure, there can be a considerable cost savings but these patients are burdened with slowly resolving vitreous opacities and membranes, which may or may not clear after months of follow-up. By contrast, pars plana vitrectomy allows early clearing of medial opacities and therefore, earlier visual rehabilitation.

When using small gauge pars plana vitrectomy, the initial vitreous specimen can be aspirated into a syringe connected into the tubing. This allows collection of a concentrated specimen for special stains and a concentrated specimen for culture. After this sample is removed from the line, the core vitrectomy can be continued. The procedure should not attempt to remove all epiretinal membranes or shave the vitreous base in most cases. After completion of the core vitrectomy portion of the surgery, antimicrobial agents can be injected prior to removal of the cannula. For eyes with more advanced corneal opacity, a 2-port transconjunctival

vitrectomy can be performed but for many eyes, a standard 3-port vitrectomy can be considered. Furthermore, small gauge vitrectomy instruments can be introduced by way of the limbus in order to remove fibrin or opacities from the anterior chamber in order to allow a better view of posterior segment details. Intravitreal antimicrobials for acute onset presumed bacterial endophthalmitis include vancomycin (1mg/0.1ml, for coverage of gram-positive bacteria) and ceftazidime (2.25mg/0.1ml, for coverage for gram-negative organisms). Because the 2 antibiotics can form precipitates when mixed together in the syringe and in the eye, the 2 antibiotic injections are given by separate syringes through the last remaining cannula port.

Published studies have reported outcomes using small gauge vitrectomy for acute onset endophthalmitis. Zhang and associates reported 21 patients with acute-onset endophthalmitis following cataract surgery who underwent small gauge (endoscope assisted 23-gauge) vitrectomy.² The visual acuity improved from baseline in 14 of 21 (66.7%) patients after treatment. In 2016, Almeida et al compared the microbiology and visual outcomes of small-gauge (23- and 25-gauge) versus 20-gauge vitrectomy among 61 patients with endophthalmitis.⁹ In this retrospective study, final visual outcomes were comparable among the 2 groups. In an in-vitro study with porcine vitreous, Magalhaes et al analyzed vitreous flow dynamics for 20-, 23-, and 25-Gauge cutters.¹⁰ The study reported different performances of vitreous removal by different vitrectomy systems. Dugel et al performed an experimental study set up to cut membranes with different vitrectomy cutters, and reported that 27-gauge probe vitrectomy has similar function and efficacy as compared to 23- and 25-gauge probes.¹¹ Furthermore, 27-gauge probe had better precision in membrane dissection and access to small tissue planes over 23- and 25-gauge vitrectomy probes. Removal of vitreous membranes in eyes with endophthalmitis is another goal of treatment with small gauge PPV. Peeling of epiretinal membranes is usually not performed at the time of initial management because of the reduced view of the retinal surface from corneal opacity, and the potential for iatrogenic complications, especially retinal tears.

SILICONE OIL

Rhegmatogenous RD in patients with endophthalmitis generally results in poor visual and anatomical outcomes. The RD can coexist at the time of presentation with endophthalmitis or may occur during the following management (during or after surgical intervention) for endophthalmitis. In the EVS, 35/420 (8.3%) patients developed RD during follow-up with more than half (16/30) of these patients resulting in visual acuity worse than 5/200 despite a high anatomic success rate of 78% (18/23).¹ In the Endophthalmitis Vitrectomy Study, there was no difference in the rate of RD between the eyes treated with TAP and inject vs. eyes treated

with pars plana vitrectomy.¹ In fact, the pars plana vitrectomy group had a slightly lower rate of postoperative RD but this difference was not statistically significant.

Silicone oil has been used traditionally in complex cases of RD with PVR or RD associated with open globe injury.⁴ In eyes presenting with concurrent or delayed onset RD and endophthalmitis, silicone oil use may be considered either during the initial PPV or during subsequent follow-up PPV (Figure 4). Silicone oil has been shown to have antimicrobial activity against *S. aureus*, *S. epidermidis*, *P. aeruginosa*, *C. albicans*, and *Aspergillus* spp., and may be utilized as an adjunct in patients with retinal detachment and endophthalmitis.⁵ In 2017, Dave et al reported the demographics, causative organisms, and treatment outcomes in 93 patients of endophthalmitis and RD, managed with silicone oil infusion.³ In this retrospective series, two groups of patients were evaluated: 1) RD at presentation (20/93, 21.5% patients) versus 2) RD occurring during follow up (73/93, 78.5% patients). The anatomical success (retina attached completely at the last visit) was achieved approximately in 70% and 98% patients while functional success (best corrected visual acuity of 20/400 or better at the last visit) was achieved approximately in 30% and 40% of these patients. None of the eyes in this series underwent enucleation or evisceration or developed phthisis bulbi. Silicone oil infusion may help in maintaining the integrity of the eye as is evident from the results of this study.

In a randomized clinical trial comparing vitrectomy with silicone oil versus vitrectomy alone for 108 patients with severe endogenous bacterial endophthalmitis, successful

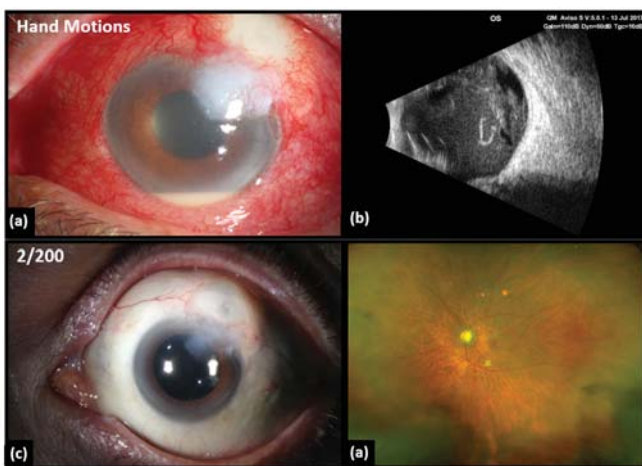


Figure 4: 4a and 4b - Bleb-associated acute endophthalmitis with marked conjunctival congestion, blebitis, adjacent corneal infiltrate, hypopyon, and vitreous exudates on B-scan. The patient had hand motions visual acuity at presentation. The patient underwent 27-G pars plana vitrectomy and injection of intraocular antibiotics. 4c and 4d - One month after surgery, infection resolved with quiet eye and fundus shows clear media and attached retina. The visual acuity returned to 2/200 which continued to improve further to 20/30 over a course of another 3-month follow-up.

outcomes (visual acuity of count fingers at 1 meter or better, with an attached retina, and no intraocular oil) at 9 months were reported to be better in the silicone oil group.¹² Pinaray et al reported a retrospective case series of 8 patients with acute endophthalmitis following intravitreal injection who underwent pars plana vitrectomy and silicone oil tamponade within 24 hours following initial vitreous tap.¹³ Endophthalmitis resolved in all these patients without occurrence of retinal detachment or phthisis bulbi during the follow-up of 1 to 4 years.

There are currently no specific guidelines for the use and dose of intravitreal antimicrobials in the silicone oil-filled eye. Pharmacokinetics and pharmacodynamics of these antimicrobial agents in silicone oil filled eye are different from an eye without silicone oil.¹⁴ In 1994, Foster et al retrospectively analyzed 16 patients with concurrent endophthalmitis and retinal detachment. In this case series 7/16 patients were managed with fluid-gas exchange, and did not receive intraocular antibiotics due to the concerns for potential retinal toxicity.¹⁵ The remaining 9/16 patients did not undergo fluid-gas exchange surgery in view of poor visual and anatomic prognosis. Although the virulence of causative organisms and time of presentation are other important factors affecting visual outcome, 2 of these 7 patients not receiving intraocular antibiotics achieved better than 20/200 vision at final follow-up visit. Foster et al discussed the potential options for using intravitreal antibiotics in the setting of fluid-gas exchange: use reduced dose of antimicrobials, or to perform a partial fluid-gas exchange to decrease the drug concentration and eventual retinal toxicity, or use infusion fluid mixed with antimicrobials after performing fluid-gas exchange.¹⁵ Mieler et al reported two cases where the combination of partial air-fluid exchange was combined with reduced dose of intraocular antimicrobials with good visual outcomes.¹⁶ Dave et al injected the full dose of intravitreal antimicrobials (antibiotic/antifungal) during surgery before silicone oil infusion. Meshi et al reported two cases in which half dose intravitreal foscarnet was injected for the management of viral retinitis in silicone oil-filled eyes and retinitis resolved in both patients. In a retrospective study, McGuire et al evaluated the efficacy of the ganciclovir implant in silicone oil filled eyes of 19 patients with cytomegalovirus retinitis.¹⁷ This study reported that ganciclovir implant was effective in silicone oil filled eyes. Martidis et al reported that ganciclovir insert was effective when implanted along with silicone oil in a case series of 10 patients with CMV retinitis-associated RD.¹⁸

ALTERNATIVE ANTIMICROBIALS

The Centers for Disease Control and Prevention (CDC), Centers for Medicare and Medicaid Services (CMS) and medication management standards (MM.09.01.01) for hospitals have provided regulations and guidelines for the an-

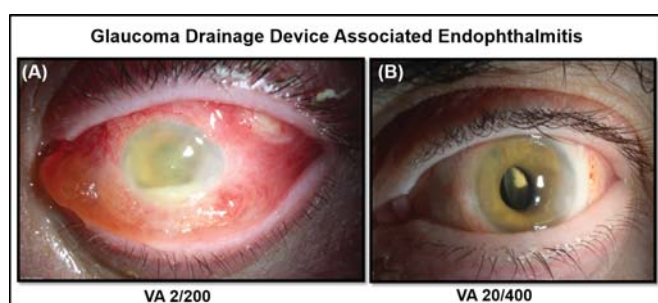


Figure 5: A 66-year-old female patient with history of prior ocular surgery (retinal detachment and glaucoma drainage implantation). (A) The patient presented with lid edema, exposed glaucoma drainage device beneath upper eyelid, conjunctival congestion, severe conjunctival chemosis, corneal edema, hypopyon, fibrinous reaction in the anterior chamber; hazy view to the posterior segment and 2/200 visual acuity. The patient underwent removal of glaucoma drainage implant, miragel scleral buckle, subconjunctival, silicone oil infusion and intravitreal vancomycin. In addition, the patient was given oral fluoroquinolones (levofloxacin) and topical vancomycin. The vitreous culture was negative for any organism. (B) At 1-year follow-up, the patient had resolution of endophthalmitis and best corrected visual acuity improved to 20/400.

tibiotic stewardship and judicious use of antimicrobials in healthcare setting to reduce the prevalence of antimicrobial resistance.⁶ With increasing antimicrobial resistance, it has become important to monitor the clinical response to the initial antimicrobials in the management of endophthalmitis. Currently, intravitreal antimicrobials including vancomycin, ceftazidime, amikacin, amphotericin and voriconazole are readily available. In cases of endophthalmitis caused by resistant organisms, alternative antimicrobial options include linezolid, quinupristin/dalfopristin, daptomycin, tigecyclin, imipenem, fluoroquinolones, miconazole or echinocandins.⁶

Povidone-iodine (0.025%) in BSS PLUS for vitreous irrigation during vitrectomy was used in 4 eyes with endophthalmitis, and visual acuity improved from light perception to hand motion before surgery to 20/200 - 120/200 after surgery.¹⁹ The intraocular lens was conserved in all four eyes. In a separate study conducted by the same group, 4 eyes with endophthalmitis were treated initially with intravitreal injection of 0.1 ml of 1.25% povidone-iodine followed by vitrectomy using 0.025% povidone-iodine in BSS PLUS for vitreous irrigation. Visual acuity was 2/200 - 20/200 before surgery, and improved further to 60/200 - 200/200 after vitrectomy. Again, the intraocular lens was saved in all 4 eyes. Corneal endothelial cell density measurement, visual field test, and electroretinographic examination revealed no adverse events attributed to povidone-iodine.²⁰ The use of intravitreal povidone-iodine for the management of endophthalmitis has been tested in rabbit experiments as povidone-iodine covers a wide range of bacteria, viruses and fungi.²¹⁻²⁴ However, the stability, safety and efficacy of intravitreal povidone-iodine remains to be established in clinical practice.²⁵

CONCLUSIONS

The use of small gauge vitrectomy, silicone oil and availability of alternative antimicrobial agents may favorably change and improve the anatomical and functional outcomes of endophthalmitis with or without retinal detachment. Currently, the management of endophthalmitis has changed from a cumbersome inpatient setting to outpatient procedure with greater efficacy, better results, and higher patient satisfaction.

Acknowledgements: We acknowledge support from the National Institute of Health (NIH) Center Core Grant P30EY014801 (Bethesda, Maryland) and Research to Prevent Blindness Unrestricted Grant (New York, New York).

Financial Disclosures: HWF and NBR - We acknowledge support from the National Institute of Health (NIH) Center Core Grant P30EY014801 (Bethesda, Maryland) and Research to Prevent Blindness Unrestricted Grant (New York, New York). SGS has received personal fees from Alimera, Bausch + Lomb, and Welch Allyn. AG reports grants, personal fees and non-financial support from Bayer, grants and non-financial support from Novartis, non-financial support from Alcon, non-financial support from Thea, personal fees and non-financial support from Valeant, non-financial support from Santen, outside the submitted work.

REFERENCES / KAYNAKLAR

1. Results of the Endophthalmitis Vitrectomy Study. A randomized trial of immediate vitrectomy and of intravenous antibiotics for the treatment of postoperative bacterial endophthalmitis. Endophthalmitis Vitrectomy Study Group. *Arch Ophthalmol* 1995;113:1479-96.
2. Zhang J, Han F, Zhai X. Clinical analysis of 23-gauge vitrectomy for the treatment of acute endophthalmitis after cataract surgery. *Eur J Ophthalmol* 2015;25:503-6.
3. Dave VP, Pathengay A, Relhan N, et al. Endophthalmitis and concurrent or delayed-onset rhegmatogenous retinal detachment managed with pars plana vitrectomy, intravitreal antibiotics, and silicone oil. *Ophthalmic Surg Lasers Imaging Retina* 2017;48:546-551.
4. Antoszyk AN, McCuen BW, 2nd, de Juan E, Jr., Machemer R. Silicone oil injection after failed primary vitreous surgery in severe ocular trauma. *Am J Ophthalmol* 1989;107:537-43.
5. Ozdamar A, Aras C, Ozturk R, Akin E, Karacorlu M, Ercikan C. In vitro antimicrobial activity of silicone oil against endophthalmitis-causing agents. *Retina* 1999;19:122-6.
6. Relhan N, Pathengay A, Schwartz SG, Flynn HW, Jr. Emerging worldwide antimicrobial resistance, antibiotic stewardship and alternative intravitreal agents for the treatment of endophthalmitis. *Retina* 2017;37:811-818.
7. Machemer R, Buettner H, Norton EW, Parel JM. Vitrectomy: a pars plana approach. *Trans Am Acad Ophthalmol Otolaryngol* 1971;75:813-20.
8. Mohamed S, Claes C, Tsang CW. Review of small gauge vitrectomy: progress and innovations. *J Ophthalmol* 2017;2017:6285869.

9. Almeida DR, Chin EK, Shah SS, et al. Comparison of microbiology and visual outcomes of patients undergoing small-gauge and 20-gauge vitrectomy for endophthalmitis. *Clin Ophthalmol* 2016;10:167-72.
10. Magalhaes O, Jr., Chong L, DeBoer C, et al. Vitreous dynamics: vitreous flow analysis in 20-, 23-, and 25-gauge cutters. *Retina* 2008;28:236-41.
11. Dugel PU, Abulon DJ, Dimalanta R. Comparison of attraction capabilities associated with high-speed, dual-pneumatic vitrectomy probes. *Retina* 2015;35:915-20.
12. Do T, Hon DN, Aung T, Hien ND, Cowan CL, Jr. Bacterial endogenous endophthalmitis in Vietnam: a randomized controlled trial comparing vitrectomy with silicone oil versus vitrectomy alone. *Clin Ophthalmol* 2014;8:1633-40.
13. Pinarci EY, Yesilirmak N, Bayar SA, Sizmaz S, Akkoyun I, Yilmaz G. The results of pars plana vitrectomy and silicone oil tamponade for endophthalmitis after intravitreal injections. *Int Ophthalmol* 2013;33:361-5.
14. Hegazy HM, Kivilcim M, Peyman GA, et al. Evaluation of toxicity of intravitreal ceftazidime, vancomycin, and ganciclovir in a silicone oil-filled eye. *Retina* 1999;19:553-7.
15. Foster RE, Rubsamen PE, Joondeph BC, Flynn HW, Jr., Smiddy WS. Concurrent endophthalmitis and retinal detachment. *Ophthalmology* 1994;101:490-8.
16. Mieler WF, Glazer LC, Bennett SR, Han DP. Favourable outcome of traumatic endophthalmitis with associated retinal breaks or detachment. *Can J Ophthalmol* 1992;27:348-52.
17. McGuire DE, McAuliffe P, Heinemann MH, Rahhal FM. Efficacy of the ganciclovir implant in the setting of silicone oil vitreous substitute. *Retina* 2000;20:520-3.
18. Martidis A, Danis RP, Ciulla TA. Treating cytomegalovirus retinitis-related retinal detachment by combining silicone oil tamponade and ganciclovir implant. *Ophthalmic Surg Lasers* 2002;33:135-9.
19. Nakashizuka H, Shimada H, Hattori T, Noguchi T, Kokubo N, Yuzawa M. Vitrectomy using 0.025% povidone-iodine in balanced salt solution plus for the treatment of postoperative endophthalmitis. *Retina* 2015;35:1087-94.
20. Shimada H, Nakashizuka H, Grzybowski A. Prevention and Treatment of Postoperative Endophthalmitis Using Povidone-Iodine. *Current pharmaceutical design* 2017;23:574-585.
21. Whitacre MM, Crockett RS. Tolerance of intravitreal povidone-iodine in rabbit eyes. *Curr Eye Res* 1990;9:725-32.
22. Trost LW, Kivilcim M, Peyman GA, Aydin E, Kazi AA. The effect of intravitreally injected povidone-iodine on *Staphylococcus epidermidis* in rabbit eyes. *J Ocul Pharmacol Ther* 2007;23:70-7.
23. Brozou CG, Karabatakis V, Giannousis M, Mandraveli K, Karkavelas G, Alexiou-Daniel S. The efficacy of intravitreal povidone iodine application in experimental *Staphylococcus epidermidis* endophthalmitis. *Ophthalmic research* 2009;41:181-5.
24. Kim KH, Cao J, Yoo JW, et al. Intraocular pharmacokinetics of povidone-iodine and its effects on experimental *staphylococcus epidermidis* endophthalmitis. *Invest Ophthalmol Vis Sci* 2015;56:6694-700.
25. Otani K, Shimada H, Nakashizuka H, Okubo H. Capsular bag irrigation using 0.025% povidone-iodine in balanced salt solution PLUS for the treatment of postoperative endophthalmitis. *Int Ophthalmol* 2017.