

The Evaluation of Choroidal Thickness in Patients With Chronic Hepatitis B Virus Infection

Kronik Hepatit B Virus Enfeksiyonu Olan Hastalarda Koroidal Kalınlığın Değerlendirilmesi

Raşit KILIÇ¹, Ali KURT¹, Bilal ERGÜL²

ABSTRACT

Aim: Our aim was to compare the choroidal thickness in patients with chronic hepatitis B virus (HBV) infection and age- and gender-matched healthy volunteers.

Materials and Methods: A total of 69 chronic HBV infection cases and 64 age- and gender-matched controls were evaluated. The chronic HBV infection cases were divided into two subgroups as inactive carriers (38 cases) and those being treated (31 cases). The right eye was evaluated in all subjects. The sections were measured horizontally across the fovea at 500- μ m intervals using enhanced depth imaging optical coherence tomography. The measurements were made at a total of 7 measurement points up to 1500 μ m nasal and temporal to the fovea.

Results: There was no significant difference between the patient and control groups in terms of age, gender, body mass index, intraocular pressure and spherical equivalent ($p>0.05$). Choroidal thicknesses in chronic HBV patients were thicker than in the controls but this difference was not statistically significant ($p>0.05$). There was no significant correlation between disease duration and choroidal thickness. There was also no significant difference between the subgroups for choroidal thickness ($p>0.05$).

Conclusions: We found that the choroidal thicknesses were higher in chronic HBV patients than in healthy control subjects at all measurement points but these differences were not statistically significant. The effect of chronic HBV infection on choroidal vascular structures is not at a significant level that can be determined with EDI-OCT.

Key Words: Choroidal thickness, chronic hepatitis B virus infection, enhanced depth imaging, optical coherence tomography.

ÖZ

Amaç: Kronik hepatit B virus (HBV) enfeksiyonu olan hastalar ile yaş ve cinsiyet yönünden benzer sağlıklı gönüllüler arasında koroidal kalınlığı karşılaştırmaktır.

Materyal ve Metod: Toplam 69 kronik HBV enfeksiyon olgusu ve 64 yaş ve cinsiyet benzer özellikte kontrol değerlendirildi. Kronik HBV enfeksiyon olguları inaktif taşıyıcılar (38 olgu) ve tedavi olanlar (31 olgu) olarak iki alt gruba ayrıldı. Tüm olgularda sağ göz değerlendirildi. Kesitler, geliştirilmiş derinlemesine görüntüleme optik koherens tomografi kullanılarak 500 μ m aralıklarla fovea boyunca horizontal olarak ölçüldü. Foveada ve nazal ve temporalde horizontal olarak foveadan 500 μ m aralıklarla 1500 mikrometreye kadar toplam 7 noktada ölçümler yapıldı.

Bulgular: Hasta ve kontrol gruplar arasında yaş, cinsiyet, vücut kitle endeksi, göz içi basıncı ve sferik eşdeğer açısından anlamlı farklılık yoktu ($p>0.05$). Koroidal kalınlık kronik HBV hastalarında daha kalın bulundu, fakat bu farklılık istatistiksel olarak anlamlı değildi ($p>0.05$). Hastalık süresi ve koroidal kalınlık arasında anlamlı bir korelasyon yoktu. Alt gruplar arasında koroidal kalınlık açısından da anlamlı farklılık yoktu ($p>0.05$).

Sonuç: Kronik HBV hastalarında koroidal kalınlığı tüm ölçüm noktalarında sağlıklı kontrollerden daha kalın bulduk, fakat bu farklılık istatistiksel olarak anlamlı değildi. Kronik HBV enfeksiyonunun koroidal damar yapıları üzerine etkisi EDI-OCT ile saptanabilen anlamlı bir düzeyde değildir.

Anahtar Sözcükler: Geliştirilmiş derinlemesine görüntüleme, koroid kalınlığı, kronik hepatit B virüs enfeksiyonu, optik koherens tomografi.

1- Yrd. Doç. Dr., Ahi Evran Üniversitesi, Tıp Fakültesi, Göz Hastalıkları Anabilim Dalı, Kırşehir, Türkiye

2- Uz. Dr., Ahi Evran Üniversitesi Eğitim ve Araştırma Hastanesi, Gastroenteroloji Kliniği, Kırşehir, Türkiye

Geliş Tarihi - Received: 10.04.2017

Kabul Tarihi - Accepted: 22.05.2017

Ret-Vit 2018; 27: 38-42

Yazışma Adresi / Correspondence Address:

Raşit KILIÇ

Ahi Evran Üniversitesi, Tıp Fakültesi, Göz Hastalıkları Anabilim Dalı, Kırşehir, Türkiye

Phone: +90 505 503 0927

E-mail: kilicrasit@gmail.com

INTRODUCTION

Despite widespread vaccination, approximately 350 million people have chronic hepatitis B virus (HBV) infection globally. The disease is usually acquired in the first few years of life in endemic regions such as Asia or Africa and it persists throughout the life of the individual. The two most important complications are hepatocellular carcinoma and cirrhosis. It is one of the most frequent causes of death globally and approximately 1 million people die every year from disorders related to chronic HBV infections.^{1,2}

The recently developed enhanced depth imaging optical coherence tomography (EDI-OCT) has enabled more detailed evaluation of the choroidal layer.³ It has been possible to obtain micrometer-level *in vivo* choroidal images with this technique, contributing to understanding the pathophysiology of disorders such as degenerative myopia, glaucoma, polypoidal choroidal vasculopathy and age-related macular degeneration (AMD).^{4,7} Systemic disorders such as diabetes mellitus and hypertension have also been reported to influence choroidal thickness.^{8,9}

The age of hepatitis B virus acquisition, viral factors and host immune factors are associated with the course of chronic HBV infection. Many cytokines such as interleukins, tumor necrosis factor alpha, and interferon- γ can cause systemic inflammation and influence the progression of disease.¹⁰ Activated T cells and B cells, increased systemic chemokines and cytokines can induce vascular damage in the whole vasculature. The choroid has one of the richest vascular structures in the body and thus, it might be more affected by systemic inflammation caused by many conditions as well as chronic HBV infection. To our knowledge, there is no previous study assessing the relationship between chronic HBV infection and choroidal thickness. We think that the systemic inflammation in chronic HBV infection can cause choroidal vascular changes and we therefore compared choroidal thickness in chronic HBV patients with healthy subjects.

MATERIALS AND METHODS

This study was conducted according to the principles of the Helsinki Declaration at Ahi Evran University Training And Research Hospital's Eye Clinic and Gastroenterology Clinic after the approval of the local ethics committee was obtained. We included 69 chronic HBV patients and 64 control subjects. All participants provided written informed consent. Only the right eye was evaluated. The chronic HBV infection cases were divided into two subgroups as inactive carriers and those being treated. The inactive carrier group consisted of patients whose serum alanine aminotransferase level was normal and HBV-DNA level under 2000 IU/ml during their 3-month follow-ups for at least one year. Treated patients were those who had cirrhosis or met treatment criteria with a liver biopsy.

All participants underwent a full ophthalmic examination and a detailed history was obtained. The ophthalmic examination consisted of visual acuity check with the Snellen chart, biomicroscopic anterior and posterior segment examination, intraocular pressure measurement with an air puff tonometer and choroidal thickness measurement with EDI-OCT. The body mass index (BMI) was calculated in all participants. Exclusion criteria were a spherical equivalent over ± 2.0 D, visual acuity below 0.8, ocular disorder or past trauma/surgery, pregnancy, diabetes mellitus, a systemic disorder such as hypertension or Behçet's disease, and the use of any ocular or systemic medication.

EDI-OCT Scan Protocol

The method of performing the EDI-OCT scan has been described previously.³ We used the EDI mode of a spectral domain OCT (Software version 6.3.3.0, Heidelberg Engineering Inc., Heidelberg, Germany). The choroidal thickness was defined as the distance between the outer reflective RPE layer and the inner sclera border. The same ophthalmologist (RK) performed all choroidal depth measurements manually (Figure 1). The sections were

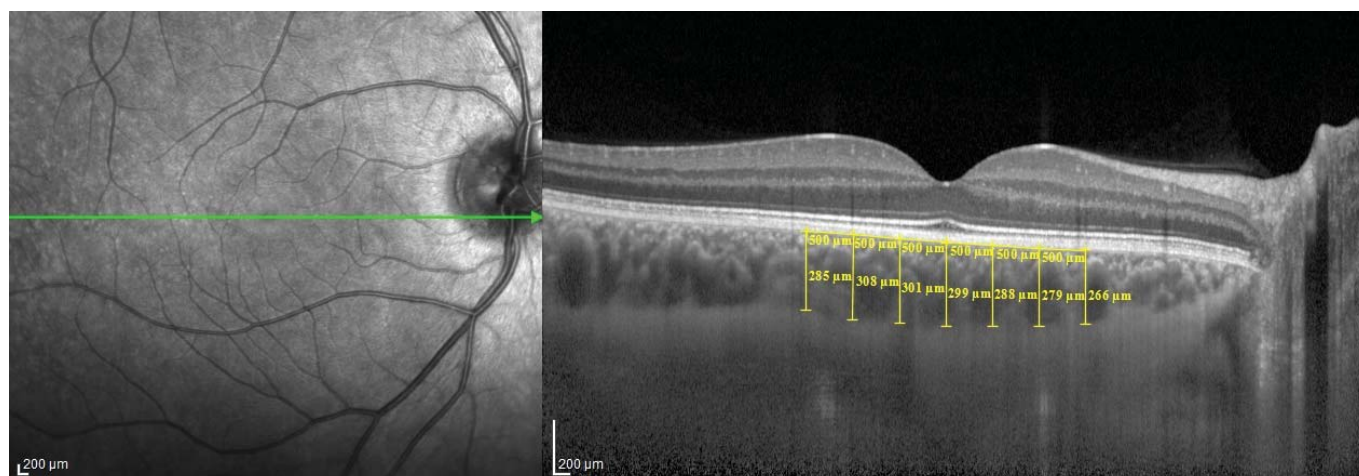


Figure 1. The manual measurement of choroidal thickness by a physician using EDI-OCT

measured horizontally across the fovea at 500- μm intervals. Choroidal thickness was measured horizontally with the digital calipers provided by the Heidelberg Spectralis software at the subfoveal region. The measurements were made at a total of 7 measurement points up to 1500 μm nasal and temporal to the fovea.

Statistical analysis

The data were analyzed with the SPSS software, version 22.0. The Kolmogorov-Smirnov test was used to determine whether the data had a normal distribution. The statistical methods used were the chi-square, independent T test and Pearson's correlation test. The results were accepted as statistically significant when p values were smaller than 0.05.

RESULTS

We evaluated the 69 eyes of 69 chronic HBV patients consisting of 38 females and 31 males and the 64 eyes of 64 control subjects consisting of 33 females and 31 males. There was no difference among the patient and control groups for age, gender, BMI, intraocular pressure and spherical equivalent ($p > 0.05$ and Table 1). The visual acuity was full in all subjects. The mean duration of the disorder was 8.3 ± 6.9 years. There was no significant difference between the patients and the control subjects for subfoveal

or other nasal and temporal choroidal thicknesses (Table 2). There was no significant correlation between disease duration and choroidal thickness ($p > 0.05$). We found no significant difference between chronic HBV patient subgroups regarding age, gender, BMI, disease duration, intraocular pressure or spherical equivalent ($p > 0.05$). There was also no difference between the subgroups for choroidal thickness ($p > 0.05$).

DISCUSSION

The choroid is of vital importance for the blood supply of the outer retina and the retinal pigment epithelium and is one of the tissues with the highest blood flow in the body. It is also important because it is the only supply for the photoreceptor cells in the fovea that have high oxygen and metabolic exchange needs.¹¹ Choroidal blood flow changes can therefore adversely affect the fovea and central vision. It is possible to obtain detailed information from the choroid by in vivo imaging using EDI-OCT. Enhanced depth imaging optical coherence tomography has therefore contributed to understanding the physiological state in the choroid and the pathology in many disorders such as central serous chorioretinopathy, age-related macular degeneration, and the Vogt-Koyanagi-Harada syndrome.^{6,12-14} Many systemic conditions can alter choroidal thickness by affecting hemodynamics.¹⁵ The effect of many systemic disorders on the choroid has therefore been investigated with EDI-

Table 1. Demographic and clinical features of chronic HBV patients and control subjects

	Chronic HBV patients (n=69)	Controls (n=64)	P
Age (mean \pm SD)	46.6 \pm 12.6	45.7 \pm 9.9	0.974
Sex (n=female/male)	38/31	33/31	0.685
Intra ocular pressure (mean \pm SD)	14.3 \pm 2.9	15.2 \pm 2.4	0.104
Spherical equivalent (mean \pm SD)	0 \pm 0.74	0.15 \pm 0.64	0.228
Body mass index (mean \pm SD)	28.2 \pm 5.1	27.9 \pm 4.3	0.728

Table 2. Choroidal thicknesses in the chronic HBV patients and control subjects

	Chronic HBV patients (n=69)	Controls (n=64)	P
CT _{n1500}	296.7 \pm 96.8	277 \pm 86.6	0.218
CT _{n1000}	324.6 \pm 99.7	302.3 \pm 88.3	0.176
CT _{n500}	340.5 \pm 104.1	321.1 \pm 87.2	0.246
Subfoveal CT	352.9 \pm 103.6	331.5 \pm 87	0.201
CT _{t500}	348.5 \pm 106.3	328.1 \pm 79.4	0.216
CT _{t1000}	336.1 \pm 102	321.6 \pm 77.6	0.359
CT _{t1500}	324.6 \pm 95	315.8 \pm 77.8	0.562

CT_{n1500}, choroidal thickness at 1500 μm nasal to the fovea; CT_{n1000}, choroidal thickness at 1000 μm nasal to the fovea; CT_{n500}, choroidal thickness at 500 μm nasal to the fovea; Subfoveal CT, choroidal thickness at the fovea; CT_{t500}, choroidal thickness at 500 μm temporal to the fovea; CT_{t1000}, choroidal thickness at 1000 μm temporal to the fovea; CT_{t1500}, choroidal thickness at 1500 μm temporal to the fovea.

OCT.^{8,9,16} The relationship between choroidal thickness and systemic immune-mediated inflammatory disorders such as ankylosing spondylitis has also been evaluated.¹⁷⁻¹⁹

Chronic HBV infection is a disorder characterized by chronic inflammatory changes that gradually affects the liver. Certain viral structural components such as HBcAg and HBeAg interact with the host immune system following HBV infection. HBV antigens can activate CD8⁺ and CD4⁺ T cells and also B cells to stimulate an immune response and produce antiviral antibodies against infected hepatocytes. The interleukins, interferons and tumor necrosis factors that are then secreted lead to damage in the hepatocytes while also causing a systemic inflammatory response.²⁰ The most common extra-hepatic manifestations associated with systemic inflammation caused by chronic HBV infection are sensory-motor deficiency, glomerulonephritis, arthritis, Raynaud's phenomenon, and myalgia while the most common ocular manifestations are uveitis and dry eye syndrome.²¹ These findings show that chronic HBV infection affects ocular structures via systemic inflammation. In addition, HBsAg has been found in the tears and aqueous humor of HBsAg seropositive patients in addition to HBV in the aqueous humor.^{22,23} However, the etiopathogenesis of ocular inflammation in chronic HBV infection still needs further elucidation.

A few studies have shown chronic HBV infection to be a risk factor for age-related macular degeneration.²⁴⁻²⁶ The molecular mimicry between retinal S-antigen and hepatitis S antigen is thought to be the cause as the cross-reactivity could possibly lead to uveoretinal inflammation. Drusen can also develop as a result of this inflammatory process.²⁷ Another explanation could be systemic inflammation triggered by chronic HBV infection as inflammation plays a crucial role in AMD pathophysiology. Based on the given information, the affected choroid by chronic HBV infection may be associated with AMD pathogenesis. The relationship between AMD and chronic HBV infection is of interest and requires new studies for clarification.

Strobbe et al.²⁸ have reported choroidal thickness and aqueous flare in chronic HCV infection and found the choroid to be thicker than in healthy control subjects. However, the study was limited to 20 cases and we therefore feel larger series are needed to fully understand the relationship between chronic HCV infection and choroidal thickness. The evidences about ocular effects of inflammation caused by chronic HBV infection, such as dry eye and uveitis, and the positive relationship between AMD and chronic HBV infection led us to carry out this study. We assumed that the systemic inflammation in chronic HBV infection could influence choroidal thickness as HCV infection. We found that the choroidal thicknesses were higher in chronic HBV patients than in healthy control subjects at all measurement

points but these differences were not statistically significant. The choroid has advanced regulation mechanism and may therefore compensate the effects of chronic and low grade systemic inflammation in chronic HBV infection.¹¹ This indicates that the effects of chronic HBV infection on choroidal vascular structures is not at a significant level that can be determined with EDI-OCT. Another explanation about our results may be associated with the difficulties determining the exact choroidal border. Low sample size of the study may also be another factor influencing on the results.

Chronic HBV infection continues to be an important issue, both with its life-threatening liver complications and with its extrahepatic complications. As far as we are aware, this is the first study to evaluate choroidal thickness in chronic HBV patients. We found no statistically significant effect of chronic HBV infection on choroidal thickness in this study but this result needs to be verified with larger studies.

COMPETING INTERESTS

The authors report no conflicts of interest. The authors alone are responsible for the content and writing of the paper.

REFERENCES / KAYNAKLAR

1. Lavanchy D. Hepatitis B virus epidemiology, disease burden, treatment, and current and emerging prevention and control measures. *J Viral Hepat* 2004; 11: 97-107.
2. Lai CL, Yuen MF. Chronic hepatitis B-new goals, new treatment. *N Engl J Med* 2008; 359: 2488-91.
3. Spaide RF, Koizumi H, Pozzoni MC. Enhanced depth imaging spectral-domain optical coherence tomography. *Am J Ophthalmol* 2008; 146: 496-500.
4. Polat OA, Sinim N, Öner A. Choroidal thickness in dry age-related macular degeneration. *Ret-Vit* 2013; 21: 265-8.
5. Ceylan C, Yılmaz YC, Özer MD, et al. Choroidal Thickness Measurement and Relationship Between Choroidal Thickness and Axial Length, Spherical Equivalent and Age in Highly Myopic Eyes. *Ret-Vit* 2015; 23: 317-20.
6. Chung SE, Kang SW, Lee JH, et al. Choroidal thickness in polypoidal choroidal vasculopathy and exudative age-related macular degeneration. *Ophthalmology* 2011; 118: 840-45.
7. Toprak I, Yaylalı V, Yildirim C. Age-based analysis of choroidal thickness and choroidal vessel diameter in primary open-angle glaucoma. *Int Ophthalmol*. 2016; 36: 171-7.
8. Unsal E, Eltutar K, Zirtiloğlu S, et al. Choroidal thickness in patients with diabetic retinopathy. *Clin Ophthalmol* 2014; 8: 637-42.
9. Ahn SJ, Woo SJ, Park KH. Retinal and choroidal changes with severe hypertension and their association with visual outcome. *Invest Ophthalmol Vis Sci* 2014; 55: 7775-85.
10. Tunçbilek S. Relationship between cytokine gene polymorphisms and chronic hepatitis B virus infection. *World J Gastroenterol* 2014; 20: 6226-35.
11. Mrejen S, Spaide RF. Optical coherence tomography: imaging of the choroid and beyond. *Surv Ophthalmol* 2013; 58: 387-429.

12. Tuncer İ, Karahan E, Zengin MÖ. Subfoveal choroidal thickness in normal eyes measurement using optical coherence tomography. *Ret-Vit* 2014; 22: 137-9.
13. Fong AH, Li KK, Wong D. Choroidal evaluation using enhanced depth imaging spectral-domain optical coherence tomography in Vogt-Koyanagi-Harada disease. *Retina* 2011; 31: 502-9.
14. Öner A, Sinim N, Arda H, et al. Central choroidal thickness in eyes with central serous chorioretinopathy: the effect of disease activity. *Ret-Vit* 2016; 24: 124-8.
15. Ulaş F, Doğan Ü, Keleş A, et al. Evaluation of choroidal and retinal thickness measurements using optical coherence tomography in non-diabetic haemodialysis patients. *Int Ophthalmol.* 2013; 33: 533-9.
16. Zengin MÖ, Karahan E, Özyurtlu F, et al. The Effect of Blood Pressure Regulation on Choroidal Thickness. *Ret-Vit* 2014; 22: 213-6.
17. Kola M, Kalkisim A, Karkucak M, et al. Evaluation of choroidal thickness in ankylosing spondylitis using optical coherence tomography. *Ocul Immunol Inflamm* 2014; 22: 434-8.
18. Onal IK, Yuksel E, Bayrakceken K, et al. Measurement and clinical implications of choroidal thickness in patients with inflammatory bowel disease. *Arq Bras Oftalmol* 2015; 78: 278-2.
19. Kılıç R, Kurt A, Acer E, et al. Choroidal thickness in psoriasis. *Int Ophthalmol.* 2017; 37: 173-7.
20. Balmasova IP, Yushchuk ND, Mynbaev OA, et al. Immunopathogenesis of chronic hepatitis B. *World J Gastroenterol* 2014; 20: 14156-71.
21. Cacoub P, Saadoun D, Bourlière M, et al. Hepatitis B virus genotypes and extrahepatic manifestations. *J Hepatol* 2005; 43: 764-70.
22. Koksai I, Cetinkaya K, Aker F. Hepatitis B surface antigen in tears and aqueous humor: a comparative study of serum hepatitis B surface antigen levels. *Ophthalmologica* 1992; 204: 19-22.
23. Tsai CY, Lin CL, Lin SC, et al. Detection of hepatitis B virus in the aqueous humor of a hepatitis B virus carrier. *Ophthalmologica* 2009; 223: 93-5.
24. Roh MI, Kim JH, Byeon SH, et al. Estimated prevalence and risk factor for age-related maculopathy. *Yonsei Med J* 2008; 49: 931-41.
25. Cho BJ, Heo JW, Kim TW, et al. Prevalence and risk factors of age-related macular degeneration in Korea: the Korea National Health and Nutrition Examination Survey 2010-2011. *Invest Ophthalmol Vis Sci* 2014; 55: 1101-8.
26. Park SJ, Lee JH, Woo SJ, et al. Epidemiologic Survey Committee of the Korean Ophthalmologic Society. Age-related macular degeneration: prevalence and risk factors from Korean National Health and Nutrition Examination Survey, 2008 through 2011. *Ophthalmology* 2014; 121: 1756-65.
27. Singh VH, Kalra HK, Yamaki K, et al. Molecular mimicry between a uveitopathogenic site of S-antigen and viral peptides. Induction of experimental autoimmune uveitis in Lewis rats. *J Immunol* 1990; 144: 1282-7.
28. Strobbe E, Cellini M, Campos EC. Aqueous flare and choroidal thickness in patients with chronic hepatitis C virus infection: a pilot study. *Ophthalmology* 2013; 120: 2258-63.