

Ophthalmic Viscoelastic Assisted Internal Limiting Membrane Flap Technique for Non-closing Macular Hole

Kapanmayan Maküla Deliği Olgularında Oftalmik Viskoelastik Yardımlı İç Limitan Membran Flep Uygulama Tekniği

Figen ŞERMET¹, Mehmet Fatih Kağan DEĞİRMENÇİ², Sibel DEMİREL³, Emin ÖZMERT¹

ABSTRACT

In this report, we aimed to present successful treatment of non-closing macular hole with a free internal limiting membrane (ILM) graft with ophthalmic viscoelastic assistance in two patients. A 66-year-old man presented with bilateral macular hole (MH) (stage 2 for the right eye and stage 4 for the left eye). After vitrectomy and ILM peeling, the MH in the left eye was not closed. 2 months later, we implanted a free ILM flap with ophthalmic viscoelastic assistance. The hole was closed one week later. Second case was a 47-year-old woman who was referred to our clinic for a macular hole in her right eye. The MH was assigned as stage 4. She underwent vitrectomy and ILM peeling. The hole was not closed postoperatively. 3 months later, the same procedure as placement a free ILM flap with ophthalmic viscoelastic assistance was performed. After the surgery the MH was closed. Placement of free ILM graft with ophthalmic viscoelastic assistance seems to be an effective technique for non-closing macular hole which was not closed after vitrectomy and ILM peeling.

Key words: Non-closing macular hole, ophthalmic viscoelastic.

ÖZ

Bu raporda cerrahi tedavi sonrası maküla deliği kapanmayan iki olguda uygulanan oftalmik viskoelastik yardımcı serbest iç limitan membran (İLM) flep uygulama tekniği bildirilmesi amaçlanmıştır. 66 yaşında olan ilk olguda bilateral maküla deliği mevcuttu (sağ gözde evre 2, sol gözde evre 4). Her iki göze farklı zamanlarda vitrektomi ve İLM soyulması uygulandı. İlk cerrahiden 2 ay sonrasında sol gözündeki maküla deliğinin kapanmaması nedeniyle oftalmik viskoelastik yardımcı serbest İLM flep uygulaması yapıldı. İkinci cerrahinin bir hafta sonrasında deliğin kapandığı görüldü. İkinci olgu ise 47 yaşında, sol gözünde maküla deliği nedeniyle kliniğe refere edilen kadın hasta idi. Vitrektomi ve İLM soyulması uygulanan hastanın maküla deliğinin kapanmaması nedeniyle 3 ay sonrasında ilk olguya benzer şekilde oftalmik viskoelastik yardımcı serbest İLM flep uygulaması yapıldı. Cerrahi sonrası birinci haftada maküla deliği kapandı. Cerrahi tedavi ile kapanmayan maküla deliği bulunan olgularda uygulanan oftalmik viskoelastik yardımcı serbest İLM flep uygulaması etkili bir teknik olarak görünmektedir.

Anahtar kelimeler: Kapanmayan maküla deliği, oftalmik viskoelastik.

INTRODUCTION

Macular hole is a pathology that causes central vision loss and there is full thickness anatomical defect of the fovea. Standard procedure for the treatment is vitrectomy combined with removal of internal limiting membrane (ILM) and intraocular gas tamponade. This surgery aims to relieve

vitreoretinal traction which is thought as main pathophysiological mechanism for macular hole. Surgical treatment of macular hole is successful as closure rates of 90% to 98%.¹ Nevertheless, there are risk factors that cause recurrence after surgery as age, duration and hole diameter.² For such cases different surgical techniques are described. Micha-

1- Prof. Dr., Ankara Üniversitesi Tıp Fakültesi, Göz Hastalıkları, Ankara, Türkiye

2- Asist. Dr., Ankara Üniversitesi Tıp Fakültesi, Göz Hastalıkları, Ankara, Türkiye

3- Yrd. Doç. Dr., Ankara Üniversitesi Tıp Fakültesi, Göz Hastalıkları, Ankara, Türkiye

Geliş Tarihi - Received: 23.04.2017

Kabul Tarihi - Accepted: 30.11.2017

Ret-Vit 2018; 27: 182-185

Yazışma Adresi / Correspondence Address:

Mehmet Fatih Kağan DEĞİRMENÇİ

Ankara Üniversitesi Tıp Fakültesi, Göz Hastalıkları, Ankara, Türkiye

Phone: +90 532 346 0288

E-mail: mfkdegirmenci@ankara.edu.tr

lewska et al.³ firstly described inverted ILM flap technique as more successful outcomes for these cases. Furthermore, in a study including 5 eyes of 5 patients with naive macular holes with a diameter greater than 600 μ , patients underwent vitrectomy combined with ILM peeling and transplantation of a small piece of free ILM flap under perfluorocarbon liquid into the macular hole.⁴ However, procedures like these are not proper for non-closing macular holes in which ILM around the hole has already been removed and it is not easy to stabilize free ILM flap under perfluorocarbon liquids.

We performed a newly defined technique for non-closing macular hole treatment as a free ILM graft with ophthalmic viscoelastic assistance in two patients.

CASE REPORT

Patient 1

A 66-year-old man, complaining progressive visual loss of his left eye for about three months, referred to our clinic. His medical history was unremarkable.

The best corrected visual acuity (BCVA) was 0.2 logMAR for the right eye and 0.7 logMAR for the left eye. Anterior segment examination showed nuclear sclerosis in both eyes. At fundoscopic examination macular hole was seen in his both eyes. According to spectral domain optical coherence tomography (SD-OCT), there was a stage 2 hole in the right eye and stage 4 in the left eye⁵. After having informed consent, the patient underwent 25-gauge pars plana vitrectomy (PPV), posterior hyaloid detachment and internal limiting membrane (ILM) peeling for right eye. At first month follow-up examination, the hole was closed. Two months after the first surgery, same procedure was performed for the left eye. But, the hole in the left eye was not closed postoperatively (Figure 1). We followed the patient for two months and decided to reoperate. This time we implaced a free flap into macular hole with the assistance of viscoelastic. One week after the procedure, fundoscopic examination and SD-OCT images showed that the macular hole was closed (Figure 2). The BCVA increased to 0.6 logMAR at first month follow-up examination and the hole was closed.

Patient 2

A 47-year-old woman was referred to our clinic for a macular hole in her right eye. She complained metamorphopsia for about four to five months. The patient had a history of cured breast cancer .

Her BCVA was 0.7 logMAR for the right eye and macular hole was seen in biomicroscopic examination. The hole was assigned as stage 4 according to SD-OCT images. Examination of the left eye was normal. 25-gauge PPV, posterior hyaloid detachment and ILM peeling was performed. At follow-up examination, the MH was not closed (Figure 3). 3

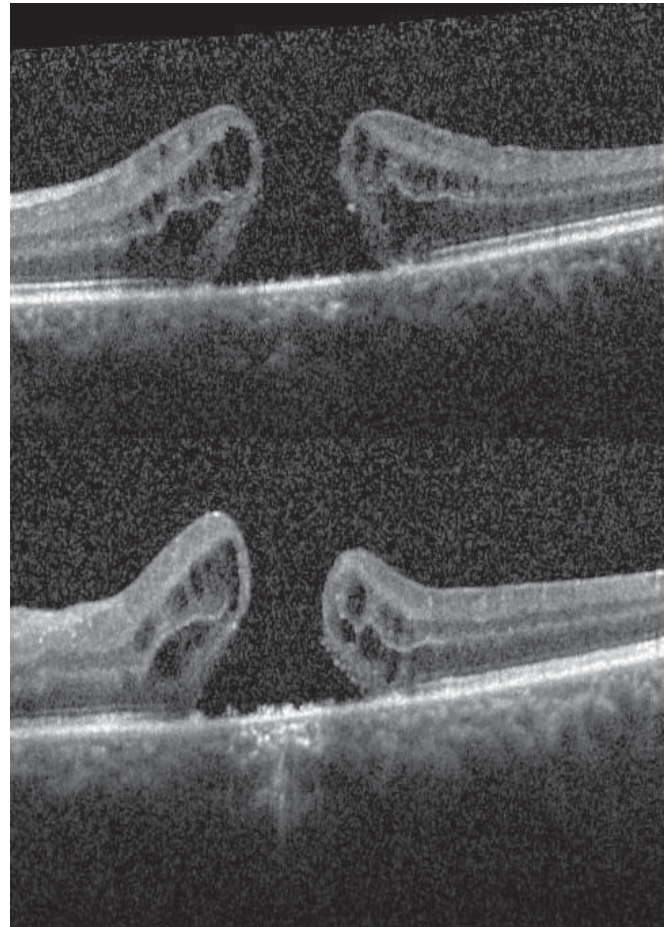


Figure 1. First patient's first surgery (preoperative and postoperative follow-up).

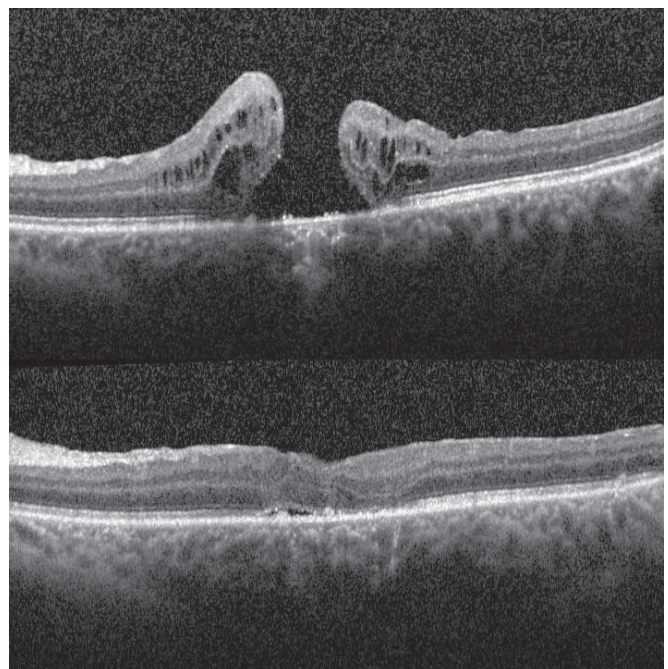


Figure 2. First patient's second surgery (preoperative and postoperative).

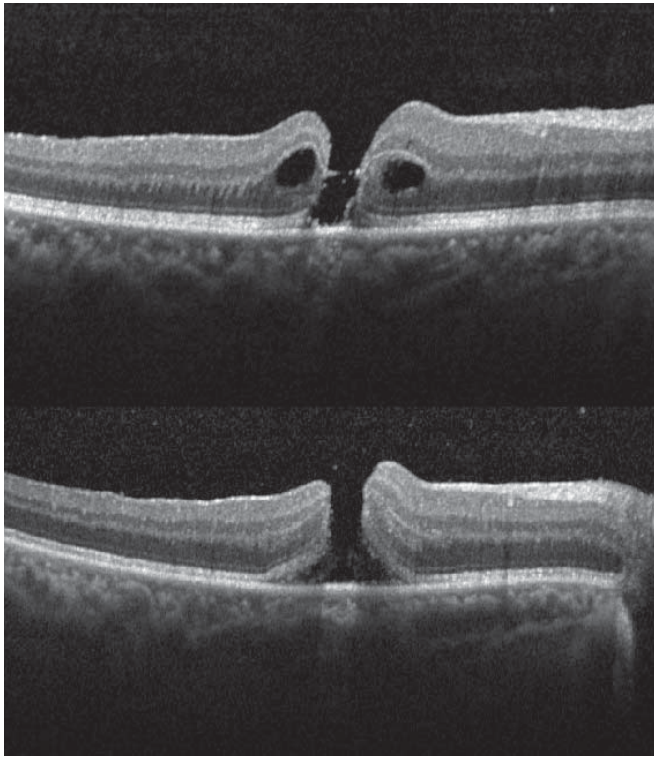


Figure 3. Second patient's first surgery (preoperative and postoperative).

months after the first surgery, same procedure as 25-gauge PPV and placement of a free flap of the remaining ILM was done. After the surgery, macular hole was closed (Figure 4). At last visit (four months later the surgery), patient's BCVA was 0.5 logMAR and the hole was closed.

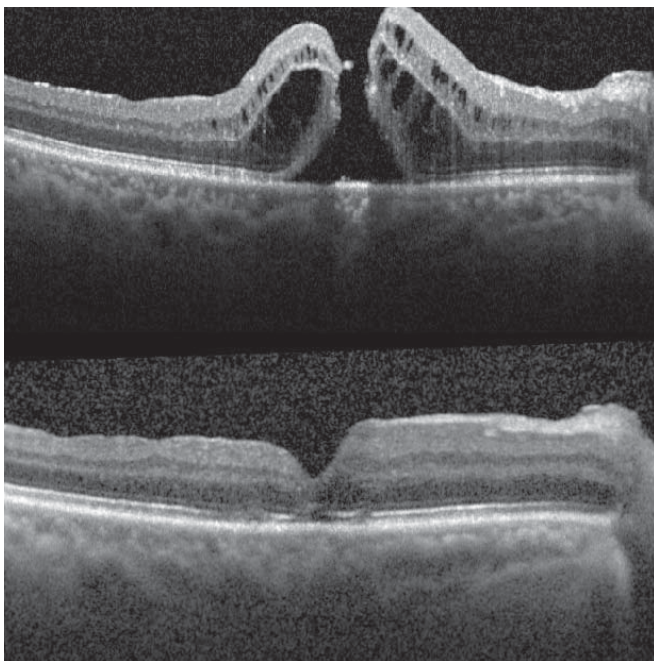


Figure 4. Second patient's second surgery (preoperative and postoperative).

SURGICAL TECHNIQUE

Pars plana vitrectomy was performed using the Constillation (Alcon Laboratories, Inc, Fort Worth, TX), 25-gauge vitrectomy system, and the noncontact wide angle viewing system (EIBOS Möller-Wedel, Wedel, Germany). Firstly, the residual ILM was stained via MembraneBlue-Dual™ (0.15% trypan blue, 0.025% brilliant blue G, 4% PEG) through injection into the vitreous cavity above the macula and followed by immediate lavage. Then, small amount of cohesive ocular viscoelastic device (OVD) (sodium hyaluronate 3% [Healon Endocoat]) was introduced over the macular hole (Figure 5). Using intraocular forceps, a free flap was picked up from the residual ILM of the previous surgery (Figure 6). The macular hole was covered with the free flap and held in position by pressing it into the hole, filled with viscoelastic, via closed forceps (Figure 7). After approval of the flap position over the hole, fluid-air and air-SF₆ (sulfur hexafluoride) exchange was performed.

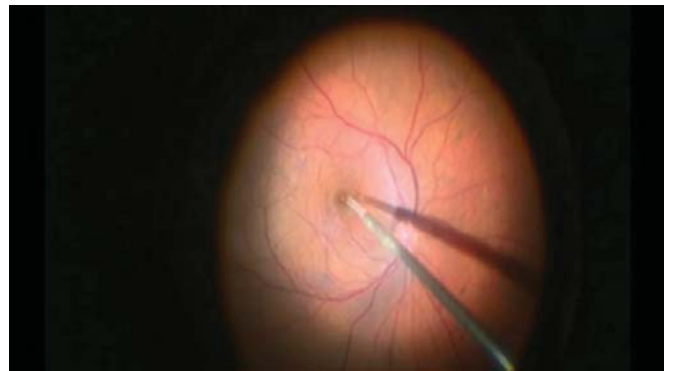


Figure 5. OVD was introduced into the macular hole place under fluid.

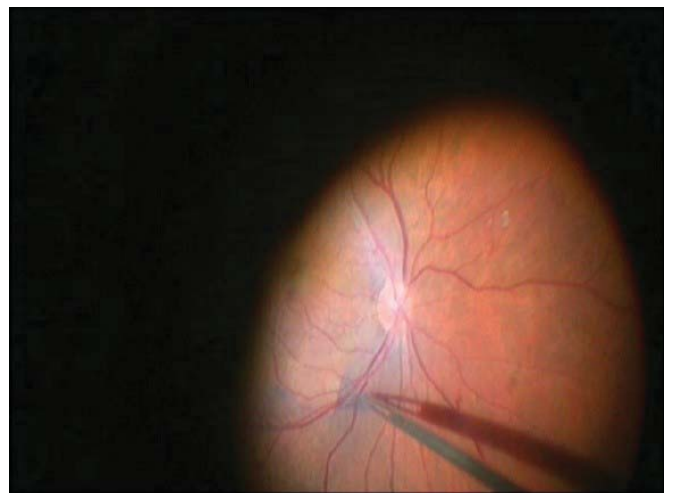


Figure 6. ILM stained with dual blue. Stained remnant ILM was removed with 25-gauge ILM forceps.

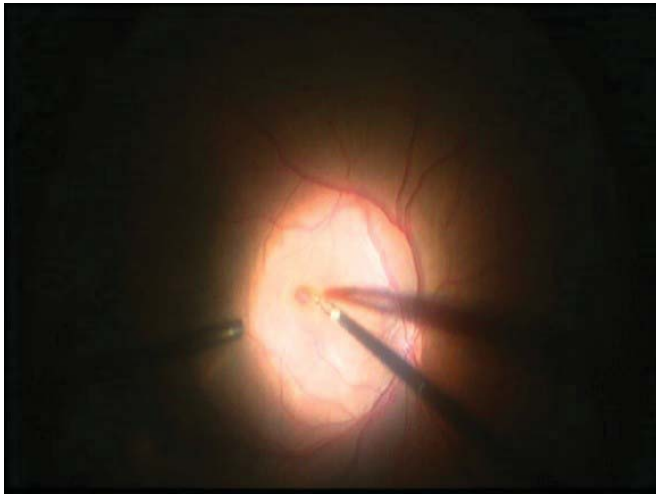


Figure 7. Free ILM flap was placed into the macular hole with same forceps.

DISCUSSION

The standart current surgical technique for macular hole treatment is vitrectomy combined with ILM removal, and it is one of the most successful operations in vitreo-retinal surgeries.¹ In cases, who have risk factors for the recurrence of the macular hole after first surgery, success rate of surgery decreases. Michalewska et al.³ reported a higher closure rate after vitrectomy using an inverted ILM flap technique for large macular holes. Recently Casini et al.⁶ used a modified procedure as macular hole was covered by the inverted ILM flap because of the air pressure at the time of the fluid-air exchange without extra flap manipulation. They reported ILM finishing, tucking, and massage may not be required to obtain surgical success. However, our 2 patients had non-closing macular hole after standard surgery and ILM around the macular hole was already been removed. Park et al.⁷ reported a new surgery as perfluoro-n-octane (PFO) assisted free

ILM flap for the recurrent macular holes of three patients and successful hole closure and restoration of the foveal depression in all patients. They used a free flap harvested from the residual ILM like used technique in our cases. While we introduced ophthalmic viscoelastic into the macular hole to stabilize the free flap during fluid-air exchange, they used a small amount of PFO over the free flap covering the macular hole.

We used a similar technique for non-closing macular hole of two patients except the stabilization technique of the free flap. This new technique is seen useful for the treatment of non-closing macular holes.

REFERENCES / KAYNAKLAR

1. Beutel J, Dahmen G, Ziegler A, Hoerauf H. Internal limiting membrane peeling with indocyanine green or trypan blue in macular hole surgery: a randomized trial. *Arch Ophthalmol* 2007;125:326-32.
2. Gupta B, Laidlaw DA, Williamson TH, Shah SP, Wong R, Wren S. Predicting visual success in macular hole surgery. *Br J Ophthalmol* 2009;93:1489-91.
3. Michalewska Z, Michalewski J, Adelman RA, Nawrocki J. Inverted internal limiting membrane flap technique for large macular holes. *Ophthalmology* 2010;117:2018-25.
4. Hernández-da Mora SE, Béjar Cornejo F. [Modified technique of autologous transplantation of internal limiting membrane for macular hole]. *Cir Cir* 2016;84:454-8.
5. Johnson RN, Gass JD. Idiopathic macular holes. Observations, stages of formation, and implications for surgical intervention. *Ophthalmol* 1988;95:917-24.
6. Casini G, Mura M, Figus M, Loiudice P, Peiretti E, De Cillà S, Fuentes T, Nasini F. Inverted internal limiting membrane flap technique for macular hole surgery without extra manipulation of the flap. *Retina* 2017;0:1-7.
7. Park SW, Pak KY, Park KH, Kim KH, Byon IS, Lee JE. Perfluoro-n-octane Assisted Free Internal Limiting Membrane Flap Technique for Recurrent Macular Hole. *Retina* 2015;35:2652-6.