

# Structural and Functional Outcomes of Retinal Displacement After Epiretinal Membrane Surgery With Internal Limiting Membrane Peeling

## Epiretinal Membran ve İç Limitan Membran Soyulması Sonrası Gelişen Retinal Yer Değiştirmenin Yapısal ve Fonksiyonel Sonuçları

Sabahattin SÜL<sup>1</sup>, Aylin KARALEZLİ<sup>2</sup>, Şafak KORKMAZ<sup>3</sup>, Kursad TOSUN<sup>4</sup>

### ABSTRACT

**Purpose:** To determine the structural and functional outcomes of retinal displacement after epiretinal membrane surgery (ERM) with internal limiting membrane (ILM) peeling.

**Materials and Methods:** The records of 56 eyes of 56 patients who underwent idiopathic ERM surgery were reviewed retrospectively. Change of fovea to optic disc (FOD) and interarcade distances (ID) at postoperative month 6 were evaluated for determination of the amount of retinal displacement. The integrity of external limiting membrane (ELM), ellipsoid zone (EZ) and cone outer segment tips (COST) and the presence of dissociated optic nerve fiber layer (DONFL) at month 6 were determined with optical coherence tomography. Corrected distance visual acuities (CDVAs) were measured before and 6 months after surgery.

**Results:** Pre and postoperative FOD were  $3668 \pm 284 \mu$  and  $3555 \pm 268 \mu$ . Pre and postoperative ID were  $7303 \pm 529 \mu$  and  $7635 \pm 575 \mu$ . ELM was intact in 46 (82%) eyes, EZ in 38 (68%) eyes and COST in 38 (68%) eyes. DONFL was detected in 40 (71%) eyes. Mean pre and postoperative CDVA were  $\log\text{MAR } 0.53 \pm 0.2$  and  $0.2 \pm 0.18$ . There was no correlation between postoperative CDVA and FOD change (Spearman's  $\rho = 0.136$ ) and ID change (Spearman's  $\rho = 0.19$ ). DONFL was significantly associated with FOD and ID change ( $p = 0.013$  ve  $p = 0.02$ , respectively). Postoperative ELM-EZ and COST integrity were not associated with FOD and ID change.

**Conclusions:** Macula seems to displace toward optic disc and expand in vertical direction following ERM and ILM peeling. There seems no correlation between retinal displacement and visual outcomes. Presence of DONFL may be related to increased retinal displacement.

**Key Words:** Epiretinal membrane, Retinal displacement, Visual acuity, Dissociated optic nerve fiber layer, Optical coherence tomography.

### ÖZ

**Amaç:** Epiretinal membran (ERM) cerrahisi ve internal limitan membran (İLM) soyulması sonrası gelişen retinal yer değiştirmenin yapısal ve fonksiyonel sonuçlarını değerlendirmek

**Gereç ve Yöntem:** İdiyopatik ERM ameliyatı yapılan 56 hastanın 56 gözünün kayıtları retrospektif olarak incelendi. Postoperatif 6. ayda fovea optik disk (FOM) ve arkuatlar arası mesafe (AAM)'deki değişim miktarı retinal yer değiştirme olarak değerlendirildi. Dış limitan membran (ELM), elipsoid zon (EZ) ve koni dış segment uçlarının (COST) bütünlüğü ve disosiyasyon optik sinir lifi tabakasının (DONFL) mevcudiyeti 6. ayda optik koherens tomografi ile belirlendi. Düzeltilmiş görme keskinlikleri (DGK) ameliyattan önce ve 6. ayda ölçüldü.

**Bulgular:** Ameliyat öncesi ve sonrası FOM  $3668 \pm 284 \mu$  ve  $3555 \pm 268 \mu$  idi. Pre ve postoperatif AAM  $7303 \pm 529 \mu$  ve  $7635 \pm 575 \mu$  idi. ELM 46 (% 82) gözde, 38'inde (% 68) EZ ve 38'inde (% 68) COST olarak sağlamdı. 40 (% 71) gözde DONFL saptandı. Ortalama preoperatif ve postoperatif DGK,  $\log\text{MAR } 0.53 \pm 0.2$  ve  $0.2 \pm 0.18$  idi. Postoperatif DGK ve FOM değişimi (Spearman'ın  $\rho = 0.136$ ) ve AAM değişimi (Spearman'ın  $\rho = 0.19$ ) arasında korelasyon yoktu. DONFL mevcudiyeti FOM ve AAM değişimi ile anlamlı olarak ilişkiliydi (sırasıyla  $p = 0.013$  ve  $p = 0.02$ ). Postoperatif ELM-EZ ve COST bütünlüğü FOM ve AAM değişikliği ile ilişkili değildi.

1- Yrd. Doç. Dr., Muğla Sıtkı Koçman Üniversitesi Tıp Fakültesi, Göz Hastalıkları, Muğla, Türkiye

2- Prof. Dr., Muğla Sıtkı Koçman Üniversitesi Tıp Fakültesi, Göz Hastalıkları, Muğla, Türkiye

3- Uz. Dr., Düzce Devlet Hastanesi, Göz Hastalıkları, Düzce, Türkiye

4- Yrd. Doç. Dr., Siena College, Biyoistatistik, New York, ABD

Geliş Tarihi - Received: 11.12.2018

Kabul Tarihi - Accepted: 21.01.2019

Ret-Vit 2019; 28: 279-284

Yazışma Adresi / Correspondence Address:

Sabahattin SÜL

Muğla Sıtkı Koçman Üniversitesi Tıp Fakültesi, Göz Hastalıkları, Muğla, Türkiye

Phone: +90 252 214 4804

E-mail: drsulgoz@gmail.com

**Sonuç:** ERM ve İLM soyulması sonrası fovea optik sinire doğru yer değiştirmekte ve AAM de genişlemektedir. Retinal yer değiştirme ile görsel sonuçlar arasında bir ilişki görünmemektedir. DONFL varlığı artmış retinal yer değiştirme ile ilişkili olabilir.

**Anahtar Kelimeler:** Epiretinal membran, Retinal yer değiştirme, Görme keskinliği, Disosisye optik sinir lifi tabakası, Optik koherens tomografi.

## INTRODUCTION

Idiopathic epiretinal membrane (ERM) is a retinal disorder that affects roughly 6% of the people over 40 years old.<sup>1</sup> It is formed by the proliferation of glial cells, fibroblasts, and astrocytes on the internal limiting membrane (ILM).<sup>2</sup> ERM is not a static retinal disorder but a dynamic condition and causes topographic changes related to contraction in the macula.<sup>3,4</sup>

Topographic changes in the macula usually resolve after surgical intervention. Pre and postoperative topographic changes have been demonstrated previously using color, red-free, fundus autofluorescence imaging and infrared images.<sup>3-6</sup> Retinal vessel movements or fixed landmarks were used to determine retinal displacement.<sup>3,7</sup>

In recent years, ILM peeling is added to pars plana vitrectomy with ERM peeling in order to decrease the recurrence rates in patients with ERM. Previously, ILM peeling was proposed as one of the components of the retinal displacement in macular holes after the surgery.<sup>8</sup> However, the effect of ILM peeling on retinal displacement has not been demonstrated in patients with ERM previously. The aim of this study is to evaluate retinal displacement following both ERM and ILM peeling and to determine the relationship between postoperative retinal displacement and visual and structural outcomes.

## METHODS

We retrospectively reviewed the records of 56 eyes of 56 patients who underwent surgical intervention for the treatment of ERM in Muğla Sıtkı Koçman University between 2015 and 2017. The study was approved by the Ethics Committee of Muğla Sıtkı Koçman University Faculty of Medicine and adhered to the tenets of the Declaration of Helsinki. Written informed consent was obtained from all of the patients before the surgical interventions.

All of the patients had idiopathic ERM. Patients with a history of previous vitreoretinal surgery, retinal vascular disease (diabetic retinopathy or vascular occlusions), uveitis, trauma or glaucoma were not included in this study. All of the patients underwent a regular ophthalmic examination including measurement of corrected distance visual acuity (CDVA) and fundus examination. Spectral-domain optical coherence tomography (OCT) (Heidelberg Engineering, Heidelberg, Germany) and color fundus photographs were carried out before and 6 months after surgery.

All of the patients underwent three-port 23 gauge (G) pars plana vitrectomy, ERM peeling in addition to a large ILM peeling (up to the vascular arcades). Staining with brilliant blue dye was performed before ERM and ILM peeling. If patients had cataract, they underwent additional cataract surgery and intraocular lens implantation before pars plana vitrectomy.

Fovea to optic disc distance (FOD) and interarcade distances (ID) were measured before and 6 months after surgery and used to evaluate retinal displacement (Figure 1 and 2). The amount of retinal displacement was defined as difference between initial (preoperative) and final (postoperative month 6) FOD and ID ( $\Delta$ FOD and  $\Delta$ ID). Additionally, integrity of external limiting membrane (ELM), ellipsoid zone (EZ), COST, presence or absence of dissociated optic nerve fiber layer (DONFL) were defined as structural outcomes and evaluated with OCT before and 6 months after surgery. Snellen CDVAs were measured before and 6 months after surgery and converted to the logarithm of minimum angle of resolution (logMAR) for statistical analyses.

**Determination of FOD:** The infrared (IR) reflectance image of OCT was used to determine the location of fovea. Fovea was identified manually on the OCT cross sections and marked on the corresponding IR image. FOD was determined by measuring the distance between the fovea and temporal edge of the optic disc using caliper tool. We defined the fovea where the outer nuclear layer was thickest and the inner nuclear layer thinnest as described previously.<sup>9</sup>

**Determination of ID:** IR images of OCT were used to determine the ID. Bifurcations or arteriovenous crossings were marked on superotemporal and inferotemporal arcuates and the distance was measured by using caliper tool.

Preoperative and postoperative central foveal thicknesses (CFT) were measured with OCT

Statistical analysis was performed using SPSS version 16 (SPSS, Chicago, IL). Spearman correlation coefficients were used to determine correlation between final CDVA and  $\Delta$ CDVA and retinal displacement. Univariate logistic regression analysis was used to delineate the association between structural outcomes and retinal displacement. A p value less than 0.05 was considered to indicate statistical significance.

## RESULTS

There were 26 (46%) women and 30 (54%) men in the study. Mean age was  $68 \pm 6.8$  years (range 50-78 years).

Mean preoperative CFT was  $447 \pm 93 \mu\text{m}$  (range 283-644 $\mu\text{m}$ ) and postoperative CFT was  $290 \pm 61 \mu\text{m}$  (range 200-480 $\mu\text{m}$ ) ( $p < 0.001$ ). Initial FOD was  $3668 \pm 284 \mu\text{m}$  (range 3098-4193), final FOD was  $3555 \pm 268 \mu\text{m}$  (range 3061-4187) and  $\Delta\text{FOD}$  was  $202 \pm 144 \mu\text{m}$  (range 23-623). Initial ID was  $7303 \pm 529 \mu\text{m}$  (range 6300-8850), final ID was  $7635 \pm 575 \mu\text{m}$  (range 6500-8950) and  $\Delta\text{ID}$  was  $412 \pm 243 \mu\text{m}$  (range 37-969). ELM was intact 46 (82%) eyes, EZ in 38 (68%) eyes and COST in 38 (68%) eyes in the preoperative assessments. At postoperative month 6, there was no additional loss of integrity of ELM, EZ and COST. DONFL was detected in 40 (71%) eyes and inner nuclear cysts were detected in 12 (21.4%) eyes. We did not encounter any cystoid macular edema during follow-up. Initial CDVA was logMAR  $0.53 \pm 0.2$  (range 0.3-1), final CDVA was  $0.2 \pm 0.18$  (range 0-0.7) and  $\Delta\text{CDVA}$  was  $0.32 \pm 0.16$  (range 0-0.7). There was no correlation between  $\Delta\text{FOD}$  and  $\Delta\text{ID}$  and final CDVA (Table 1). Additionally, there was no correlation between  $\Delta\text{CDVA}$  and  $\Delta\text{FOD}$  and  $\Delta\text{ID}$  change (Table 1). DONFL was significantly associated with  $\Delta\text{FOD}$  and  $\Delta\text{ID}$  ( $p = 0.013$  ve  $p = 0.02$ , respectively). Postoperative ELM-EZ and COST integrity were not associated with  $\Delta\text{FOD}$  and  $\Delta\text{ID}$  (Table 2).

## DISCUSSION

In this study, we used fixed landmarks to determine the amount of retinal displacement. Our approach was similar to that of Rodrigues et al. where fixed landmarks including fovea to optic disc and interarcade distances were used to evaluate retinal displacement.<sup>7</sup> Current study found that macula expanded in the vertical direction similar with Rodrigues et al.<sup>7</sup> However, fovea displaced toward optic disc following peeling of both ERM and ILM. Those studies

which have found movement of fovea in the opposite direction of optic disc or no movement of fovea, included the patients who underwent ERM removal without ILM peeling.<sup>6,7</sup> We additionally performed a large ILM peeling after ERM peeling and found the nasal displacement of the fovea. ILM peeling have been shown the cause of nasal displacement of fovea following macular hole surgery.<sup>10</sup> Contractile forces of retinal nerve fiber layer which have emerged following ILM peeling was proposed as one of the causes of foveal displacement toward optic disc.<sup>11</sup>

Increased preoperative retinal displacement due to epiretinal membrane contraction has been associated with decreased initial visual acuity.<sup>3,4</sup> In addition, decreased preoperative visual acuity has been associated with worse postoperative visual acuity.<sup>6</sup> Retinal displacement following surgery may be expected more in those patients who have low initial visual acuity and large preoperative retinal displacement. In other words, patients with a large postoperative retinal displacement would be expected to have worse final CDVA. However, there was no correlation between final CDVA,  $\Delta\text{CDVA}$  and retinal displacement in this study. First, both retinal displacement and CDVA may have been improved simultaneously as stated by Lo et al.<sup>4</sup> Second, addition of ILM peeling to ERM peeling may have changed the amount of retinal displacement owing to the contractile forces of nerve fiber.<sup>7,10</sup> In addition, Ray et al. have showed that the actual movement of retina over the retinal pigment epithelium may be possible in ERM cases.<sup>12</sup> The movement of the retina may not have a harmful effect over the outer retinal structures which have also been showed as prognostic factors for final CDVA.<sup>13,14</sup> Indeed, there was no association between the postoperative integrity of outer retinal structures including

**Table 1.** Correlations between retinal displacement and visual acuities (Spearman's Rho).

Initial CDVA	Final CDVA	$\Delta\text{CDVA}$	
$\Delta\text{FOD}$	rho=0.124 p=0.362	rho=0.136 p=0.317	rho=0.094 p=0.490
$\Delta\text{ID}$	rho=0.168 p=0.216	rho=0.192 p=0.156	rho=-0.004 p=0.974

$\Delta$ : difference between initial and final (postoperative month 6) measurements **FOD**: Fovea to optic disc distance **ID**: Interarcade distance **CDVA**: Corrected distance visual acuity

**Table 2.** Association between structural outcomes and retinal displacement (Logistic regression analysis).

	$\Delta\text{FOD}$		$\Delta\text{ID}$	
	p	Odds	p	Odds
<b>ELM</b>	0.295	0.793	0.632	1.076
<b>EZ</b>	0.090	0.712	0.245	0.872
<b>COST</b>	0.090	0.712	0.245	0.872
<b>DONFL</b>	<b>0.013</b>	<b>3.131</b>	<b>0.02</b>	<b>1.511</b>
<b>INC</b>	0.125	0.592	0.980	1.003

$\Delta$ : difference between initial and final (postoperative month 6) measurements **FOD**: Fovea to optic disc distance **ID**: Interarcade distance **ELM**: External limiting membrane **EZ**: Ellipsoid zone **COST**: Cone outer segment tips **DONFL**: Dissociated optic nerve fiber layer **INC**: Inner nuclear cyst

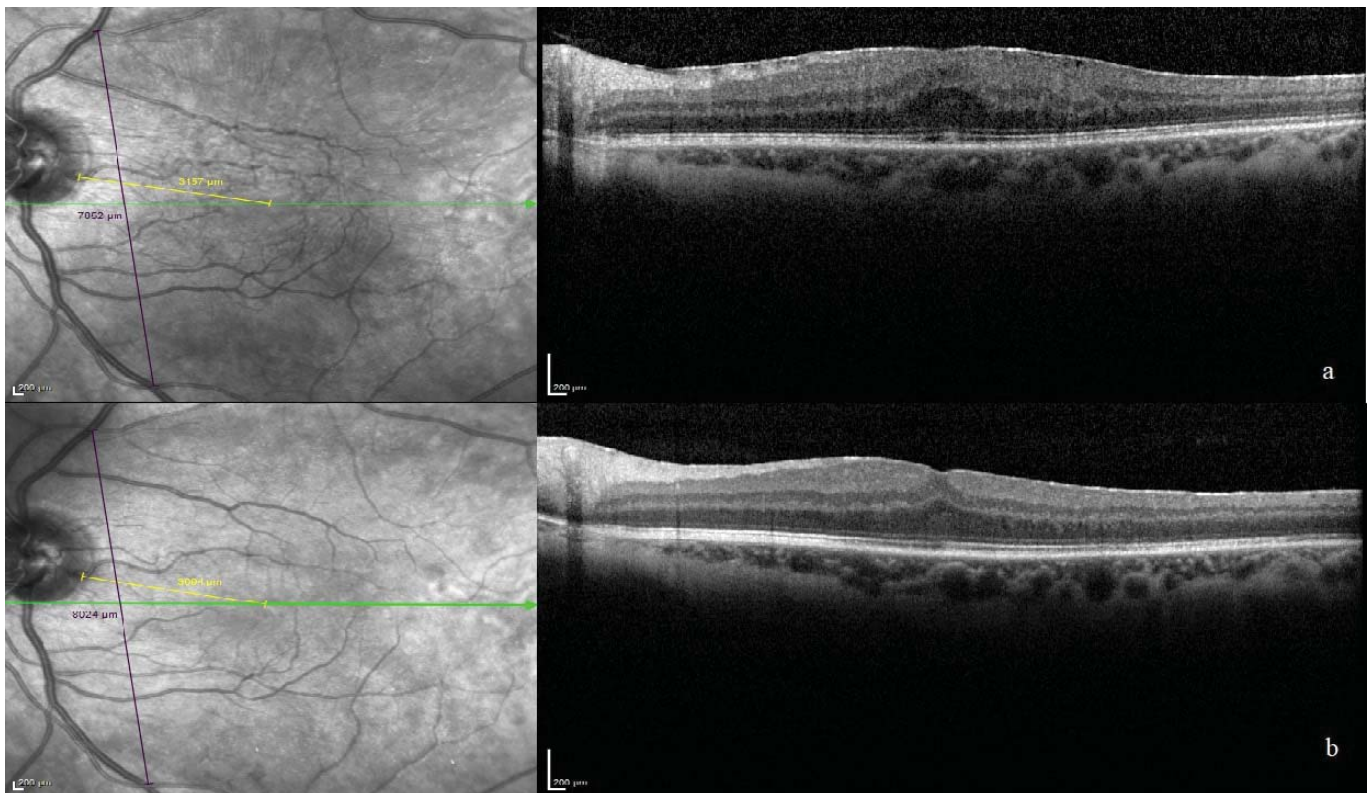
ELM - EZ and COST and retinal displacement. Furthermore, a previous study has shown that ILM peeling had a harmful effect on photoreceptor layer owing to mechanical damage during manipulation.<sup>15</sup> However, we did not encounter an additional postoperative integrity loss in eyes which had intact preoperative ELM, EZ and COST lines.

In this study, DONFL appearance was seen in 77% of the patients which was consistent with the literature.<sup>16,17</sup> ILM peeling area greater than one disc diameter and using gas endotamponade have been suggested as the causes of DONFL development.<sup>18,19</sup> In the current study, we did not use intravitreal gas endotamponade but performed large size (up to the vascular arcades) ILM peeling to prevent recurrence. Besides, DONFL appearance may be related to the amount of postoperative retinal displacement in other words increased retinal mobility in the current study (Figure 1a and b and Figure 2a and b), which was similar with Nakagomi et al.<sup>20</sup> Nakagomi et al. have concluded that increased macular slippage would have been a reasonable cause of DONFL appearance. ILM is the endplates of Müller cells which ensheath and hold nerve fiber bundles close together.<sup>21</sup> ILM peeling causes loss of Müller cell glial processes which provide structural support to all retinal layers.<sup>22-24</sup> Therefore, loss of structural support is thought to

separate nerve fiber bundles into a dissociated structure.<sup>24</sup> In addition, increased macular mobility (increased FOD and ID change) following removal of ERM and ILM peeling may trigger morphological alterations in the nerve fiber layer in the absence of structural support and result with DONFL appearance.

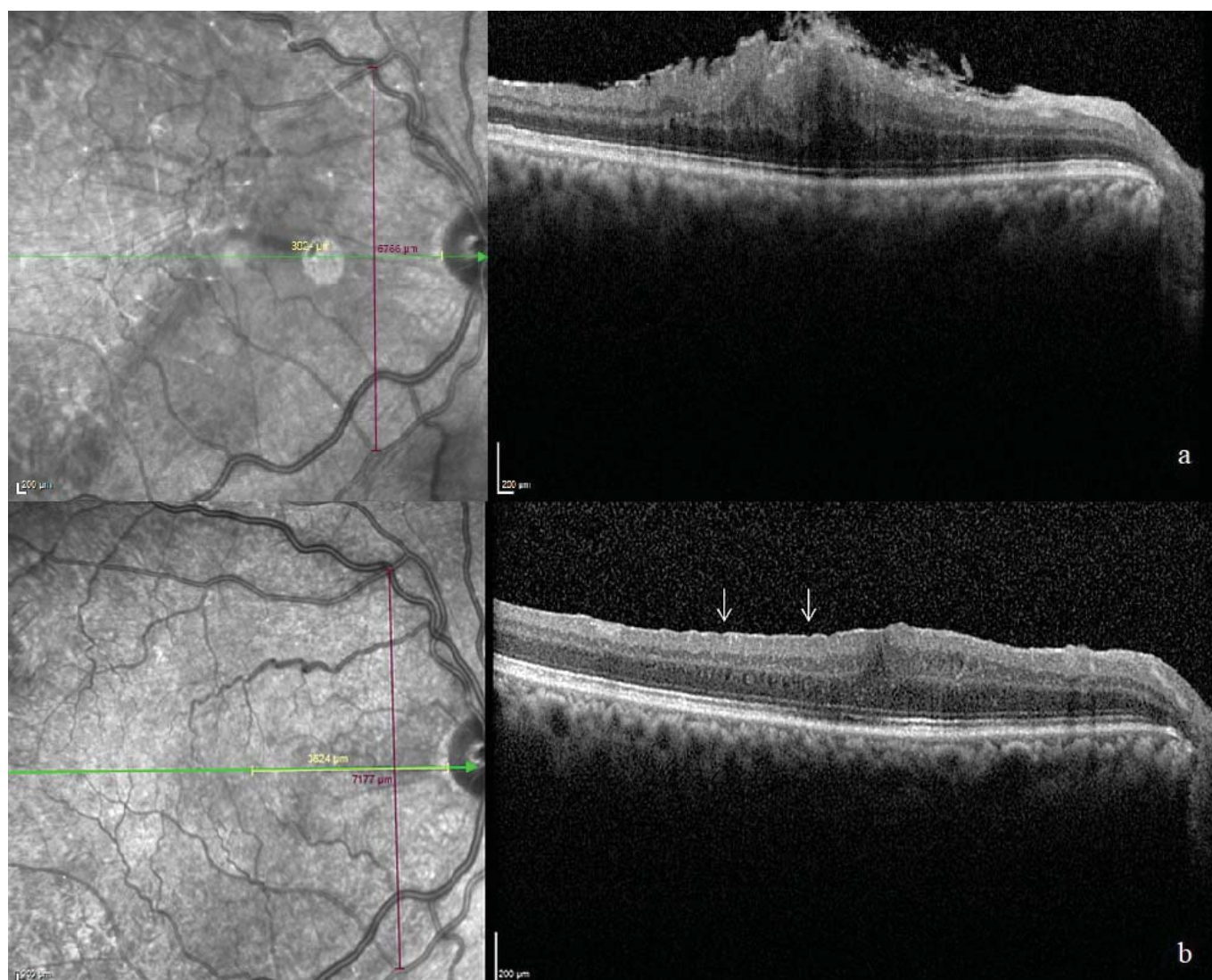
Our study has several limitations. First, the study design was retrospective. Second, we only used BCVA as an index for visual outcomes. Since metamorphopsia affects a patient's visual quality, assessments of various aspects of visual outcomes are required. On the other hand, the current study is the first study which evaluates retinal displacement following both ERM and ILM peeling. In addition, relationship between DONFL appearance and the amount of retinal displacement is an interesting finding of this study.

In conclusion, macula appear to expand in the vertical plane following ERM removal, however, it displaces towards optic disc when additional ILM peeling is performed. Initial and final visual acuities are not correlated with retinal displacement. However, absence of correlation may be the effect of additional ILM peeling on retinal displacement. Furthermore, increased retinal displacement seems to be associated with DONFL development following ILM peeling.



**Figure 1a.** Measurement of preoperative fovea to optic disc (yellow line) and interarcade distances (Purple line). Fovea was identified manually on the optical coherence tomography cross sections and marked on the corresponding infrared image.

**Figure 1b.** Measurement of postoperative fovea to optic disc (yellow line) and interarcade distances (Purple line). The patient had small foveal ( $63\mu$ ) and vertical displacement ( $172\mu$ ) following surgery. Dissociated optic nerve fiber layer was not detected at month 6.



**Figure 2a.** Preoperative infrared and B-scan optical coherence tomography image of a patient.

**Figure 2b.** Postoperative infrared and B-scan optical coherence tomography image of the same patient. The patient had a large foveal ( $300\mu$ ) and interarcade displacement ( $411\mu$ ) following surgery. Dissociated optic nerve fiber layer (white arrows) was detected at month 6.

## REFERENCES / KAYNAKLAR

1. McCarty D, Mukesh B, Chikani V, et al. Prevalence and associations of epiretinal membranes in the visual impairment project. *Am J Ophthalmol* 2005;140:288-94.
2. De Bustros S, Thompson JT, Michels RG, et al. Vitrectomy for idiopathic epiretinal membranes causing macular pucker. *Br J Ophthalmol* 1988;72:692-5.
3. Kofod M, la Cour M. Quantification of retinal tangential movement in epiretinal membranes. *Ophthalmology* 2012;119(9):1886-91.
4. Lo D, Heussen F, Ho HK, et al. Structural and functional implications of severe foveal dystopia in epiretinal membranes. *Retina* 2012;32(2):340-8.
5. Weinberger D, Stiebel-Kalish H, Priel E, et al. Digital red-free photography for the evaluation of retinal blood vessel displacement in epiretinal membrane. *Ophthalmology* 1999;106:1380-3.
6. Yang HK, Kim SJ, Jung YS, et al. Improvement of horizontal macular contraction after surgical removal of epiretinal membranes. *Eye* 2011;25:754-61.
7. Rodrigues IA, Lee EJ, Williamson TH. Measurement of retinal displacement and metamorphopsia after epiretinal membrane or macular hole surgery. *Retina* 2016;36:695-702
8. Kawano K, Ito Y, Kondo M, et al. Displacement of foveal area toward optic disc after macular hole surgery with internal limiting membrane peeling. *Eye* 2013;27:871-7.
9. Ichikawa Y, Imamura Y, Ishida M. Metamorphopsia and tangential retinal displacement after epiretinal membrane surgery. *Retina* 2017;37:673-9
10. Pak KY, Park KH, Kim KH, et al. Topographic changes of the macula after closure of idiopathic macular hole. *Retina* 2017;37:667-72
11. Ishida M, Ichikawa Y, Higashida R, et al. Retinal displacement toward optic disc after internal limiting membrane peeling for idiopathic macular hole. *Am J Ophthalmol* 2014;157:971-7
12. Ray R, Barañano DE, Fortun JA, et al. Intraoperative microscope-mounted spectral domain optical coherence tomography for

- evaluation of retinal anatomy during macular surgery. *Ophthalmol* 2011;118:2212-7.
13. Theodossiadis PG, Theodossiadis GP, Charonis A, et al. The photoreceptor layer as a prognostic factor for visual acuity in the secondary epiretinal membrane after retinal detachment surgery: imaging analysis by spectral-domain optical coherence tomography. *Am J Ophthalmol* 2011;151:973-80.
  14. Shimozone M, Oishi A, Hata M, et al. The significance of cone outer segment tips as a prognostic factor in epiretinal membrane surgery. *Am J Ophthalmol* 2012;153:698-704.
  15. Ahn SJ, Ahn J, Woo SJ, et al. Photoreceptor change and visual outcome after idiopathic epiretinal membrane removal with or without additional internal limiting membrane peeling. 2014; *Retina* 34:172-81
  16. Tadayoni R, Paques M, Massin P, et al. Dissociated optic nerve fiber layer appearance of the fundus after idiopathic epiretinal membrane removal. *Ophthalmology* 2001;108:2279-83
  17. Alkabes M, Salinas C, Vitale L, et al. En face optical coherence tomography of inner retinal defects after internal limiting membrane peeling for idiopathic macular hole. *Invest Ophthalmol Vis Sci* 2011;52(11):8349-55
  18. Haritoglou C, Gandorfer A, Kampik A. NFL appearance after peeling. *Ophthalmology* 2006;113: 1690; author reply 1690–1691.
  19. Park SH, Kim YJ, Lee SJ. Incidence and risk factors for dissociated optic nerve fiber layer after epiretinal membrane surgery. *Retina* 2016;36:1469-73
  20. Nakagomi T, Goto T, Tateno Y, et al. Macular slippage after macular hole surgery with internal limiting membrane peeling. *Curr Eye Res* 2013;38(12):1255-60
  21. Hollander H, Makarov F, Dreher Z, et al. Structure of the macroglia of the retina: sharing and division of labour between astrocytes and Müller cells. *J Comp Neurol* 1991;313:587-603.
  22. Nakamura T, Murata T, Hisatomi T, et al. Ultrastructure of the vitreoretinal interface following the removal of the internal limiting membrane using indocyanine green. *Curr Eye Res* 2003;27:395-9.
  23. Hisatomi T, Notomi S, Tachibana T, et al. Ultrastructural changes of the vitreoretinal interface during long-term follow-up after removal of the internal limiting membrane. *Am J Ophthalmol* 2014;158:550-6.
  24. Hisatomi T, Tachibana T, Notomi S, et al. Incomplete repair of retinal structure after vitrectomy with internal limiting membrane peeling. *Retina* 2017;37(8):1523-8.