

Retinal Cadmium Accumulation in a Worker at a Locomotive Factory

Tolga Biçer¹ , Neşe Arslan Avarisli¹

ABSTRACT

The accumulation of cadmium (Cd) in the retina is an unusual condition and it can be seen as a result of long-term occupational exposure. The lesion seen in the retina was considered as a Cd accumulation if there was a high rate of Cd in the blood and urine. The aim of this case report is to describe retinal Cd accumulation due to high-dose Cd exposure in a patient working in a locomotive factory. A male patient, who has a high rate of Cd accumulation in the blood and diagnosed as cadmium-induced polyneuropathy, underwent an examination of the eye. Best-corrected visual acuity, contrast sensitivity, and intraocular pressure measurements were normal. There were retinal pigment epithelium changes and hyper-reflected lesions in optical coherence tomography images and fundus autofluorescence images. Retinal Cd accumulation is unusual, but it can be seen as a result of long-term occupational exposure, especially in the metal industry.

Keywords: Hyper-reflectance, Cadmium accumulation, RPE, Heavy metal induced retinopathy.

INTRODUCTION

Heavy metals, such as lead, cadmium (Cd), mercury, carry potential risk for accumulation and have toxic effects in human cells.

They cause permanent contamination of air, dust, and soil. The human eye can also be affected by the accumulation of Cd. The pigmented ocular tissues, such as retinal pigment epithelium, choroid, ciliary body, have a higher risk of accumulation¹. The retinal pigment epithelium is a metal-chelating tissue that is capable of binding essential and toxic heavy metals. The elements have a high affinity to melanin in retinal pigment epithelium melanosomes². Workers in heavy metal industries should undergo physical examination periodically.

CASE REPORT

A healthy 41-year-old man was referred to the department of ophthalmology from the department of neurology. He had been following for the diagnosis of polyneuropathy related to a high rate of Cd accumulation in his blood and urine for two years. In his medical history, we learned that

he had been working in a locomotive factory for six years. He had no surgery before, and diseases such as diabetes mellitus and hypertension. Also, he was a non-smoker and did not use any medication. There was no macular degeneration near the 1st-degree relatives. His complaints were blurred vision and increased light sensitivity that happened occasionally.

He underwent a full ophthalmic examination. His best-corrected visual acuity was 20/20 and intraocular pressure measurement was 17-18 mmHg in the right and left eyes, respectively. Autorefractometric measurement was emmetrope. Contrast sensitivity, color vision, and visual field tests were normal. After dilatation with 1% tropicamide, retinal pigment epithelium (RPE) changes were observed in inferonasal of both fovea (Figure 1) by colored fundus photography. Spectral-Domain Optical Coherence Tomography (SdOCT) showed hyper-reflected lesions in both foveal nasal RPE levels (Figure 2). Fundus autofluorescence (FAF) images showed hyper-reflected areas at similar localization (Figure 3).

1- MD, University of Health Sciences, Dışkapı Yıldırım Beyazıt Education and Research Hospital, Department of Ophthalmology, Ankara, Turkey

Received: 09.05.2020

Accepted: 10.07.2020

Ret-Vit 2021; 30:299-302

DOI: 10.37845/ret.vit.2021.30.52

Correspondence Address:

Tolga Biçer

University of Health Sciences, Dışkapı Yıldırım Beyazıt Education and Research Hospital, Department of Ophthalmology, Ankara, Turkey

Phone: +90 532 513 8022

E-mail: drtolgabicer@yahoo.com

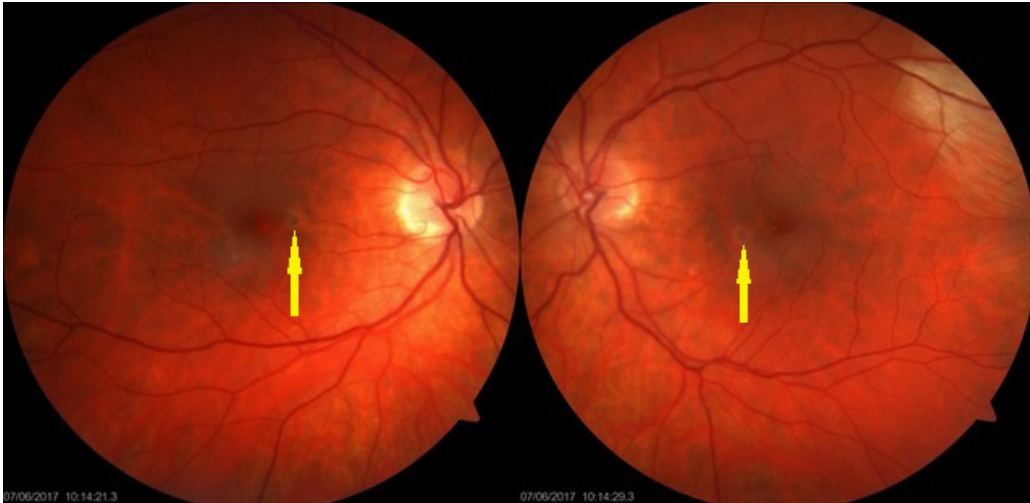


Figure 1: Colored fundus photography shows retinal pigment epithelium (RPE) changes in inferonasal regions of both fovea (arrows).

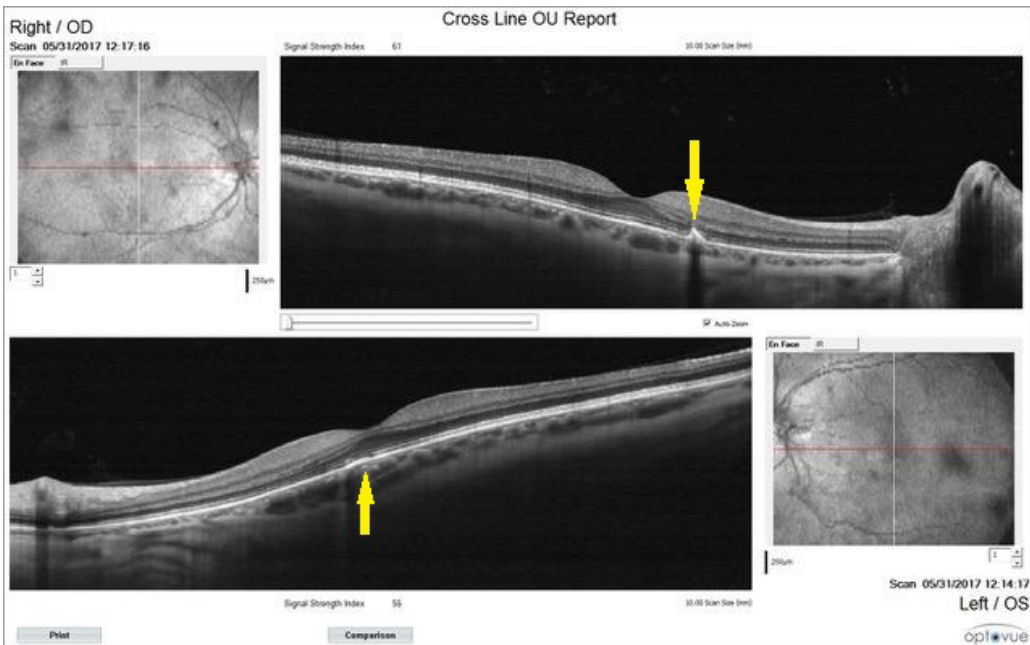


Figure 2: Hyper-reflective lesions in both foveal nasal RPE levels can be seen (arrows) in SdOCT* images. * SdOCT: Spectral Domain Optic Coherence Tomography.

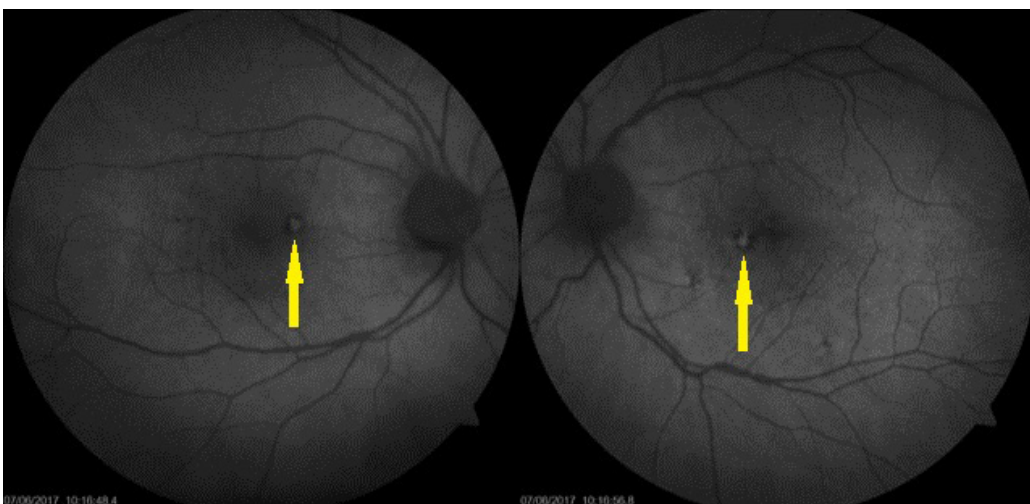


Figure 3: Fundus autofluorescence (FAF) images show hyper-reflective areas in both foveal nasal regions (arrows).

DISCUSSION

Cd is an industrial pollutant that causes permanent contamination of air, dust, and soil. Heavy metals are released into the environment from fossil fuel power plants, mining, and smelting of metal ores, trash incineration, and combustion of leaded gasoline¹. In non-occupationally exposed populations, the main sources of Cd are tobacco smoke, ingestion of contaminated food³. Cd toxicity related to prolonged exposure has been associated with renal disease, hypertension, and an increased prevalence of cardiovascular disease⁴.

Cd accumulates in the tissues of the human retina, primarily in the highly pigmented retinal pigment epithelium (RPE) and choroid. The pigmented tissues of the eye, such as the RPE, choroid, iris, and ciliary body, include high amounts of melanin and have a high affinity for metal ions. Melanin within the pigment granules binds metal ions². In our patient, SdOCT and FAF images showed hyper-reflected lesions in both RPE layers.

In a study, it has been reported that, in the eyes of lizards living in the soil containing high levels of Cd macroscopically as anophthalmia and microphthalmia, at the cytological level, as retinal dysplasia and retinal foldings, probably due to a loss of control over the proliferative processes⁵. Their data supported that Cd increased expression of Pax6 and Otx2 genes, interfering with cell cycle regulation by increasing proliferation. In vertebrates, both genes have been implicated in the control of cell proliferation and specification in the retina⁶.

In our patient, it was thought that hyperpigmented lesion in the RPE level might be due to the proliferation in RPE cells, or the accumulation of Cd which is phagocytosed by RPE.

Avallone et al. stated that Cd induces severe significant microscopic and macroscopic degeneration and toxic effects such as loss of retinal organisation, and consequent impairment of the functional response, mainly through increased light sensitivity in adult zebrafish⁷.

Gungor et al, stated that copper (Cu) and zinc (Zn) are essential for functioning of antioxidant metalloenzymes found in RPE cells. Cd and lead (Pb) displace Cu and Zn and block the binding sites of these metals. The depletion

of intracellular Cu and Zn might increase the oxidative stress and cause apoptosis of RPE cells. They compared age related macular degeneration (AMD) and control groups. According to their study there was no statistically significant difference between Pb and Cd levels in blood. In conclusion, they stated that blood Pb and Cd levels which reflect short term exposure were not significantly different in AMD patients and the control group⁸. Our case had been working in a locomotive factory for six years and was followed up for two years with a diagnosis of Cd-induced toxic polyneuropathy by the department of neurology. Long term exposure should be the most important factor for accumulation of heavy metals in RPE cells.

Subretinal drusenoid deposits, talc accumulation, crystalline deposits such as tamoxifen, and long time exposure to heavy metals such as Pb, mercury, cadmium, manganese, and zinc may be considered in the differential diagnosis, causing a hyper-reflective spot at the RPE level.

In our study, we thought that the accumulation of cadmium might be due to the patient's occupation. He had been a factory worker for a long time, had a high level of cadmium in the blood and diagnosed with Cd-induced toxic polyneuropathy. There were no risk factors for other diseases or exposures included in the differential diagnosis.

OCT findings of the conditions included in differential diagnosis are usually the same and may not give any diagnostic findings. One of the most important factors for the accumulation of heavy metal in any tissue is occupational exposure. We can distinguish the metal or drug toxicities by taking the medical history, drug usage and occupational properties carefully.

The patients' complaints were blurred vision and increased light sensitivity that happened occasionally. Visual acuity, contrast sensitivity and visual field tests were normal. The normal findings may be due to the early detection and parafoveal location of the Cd accumulation.

Examination of the people working in the heavy metal factory at regular intervals is important for the early detection of this type of metal accumulation. Full ophthalmic examination and monitoring of the ocular tissues should be performed regularly.

REFERENCES

1. Erie JC, Butz JA, Good JA, et al. Heavy metal concentrations in human eyes. *Am J Ophthalmol* 2005;139:888-93.
2. Larsson BS. Interaction between chemicals and melanin. *Pigment Cell Res* 1993;6:127-33.
3. Garner R, Levallois P. Cadmium levels and sources of exposure among Canadian adults. *Health Rep* 2016;27:10-8.
4. Satarug S, Baker JR, Urbenjapol S, et al. A global perspective on cadmium pollution and toxicity in non-occupationally exposed population. *Toxicol Lett* 2003;137:65-83.
5. Simoniello P, Trinchella F, Filosa S, et al. Cadmium contaminated soil affects retinogenesis in lizard embryos. *J Exp Zool A Ecol Genet Physiol* 2014;321:207-19.
6. Hever AM, Williamson KA, Van Heyningen V. Developmental malformations of the eye: the role of PAX6, SOX2 and OTX2. *Clin Genet* 2006;69:459-70.
7. Avallone B, Crispino R, Cerciello R, et al. Cadmium effects on the retina of adult *Danio rerio*. *C R Biol* 2015;338:40-47.
8. Damar Güngör E, Yülek F, Serkant U, et al. Blood lead and cadmium in age related macular degeneration in a Turkish urban population. *J Trace Elem Med Biol*. 2018;48:16-19. doi:10.1016/j.jtemb.2018.02.019