

# Outcomes of Free Internal Limiting Membrane Flap Transplantation Surgery with Silicone Oil Tamponade for Large or Persistent Idiopathic Macular Holes

Ece Ozal<sup>1</sup>, Sadik Altan Ozal<sup>2</sup>, Sultan Kaya<sup>3</sup>

## ABSTRACT

**Purpose:** To report anatomical and functional results in cases where we applied free internal limiting membrane (ILM) flap transplantation as primary or secondary surgery in large or persistent idiopathic macular holes (MHs).

**Materials and Methods:** Ten eyes of 10 consecutive patients who underwent free ILM flap transplantation combined with pars plana vitrectomy surgery due to large or persistent MHs (diameter > 400 µm), and who used silicone-oil as an endotamponade were reviewed retrospectively. All patients underwent detailed ophthalmological examination and optical coherence tomography measurements at the first, third, sixth, and twelfth months postoperatively. Silicone-oil was removed in all cases at the third months postoperatively. The rates of anatomical closure, best-corrected visual acuity (BCVA) values, and ellipsoid zone disruption (EZD) values were compared within the preoperative and postoperative periods.

**Results:** The mean age of the patients was 69.20±4.94 years. Seven patients (70.0%) were female, and 3 patients (30.0%) were male. Anatomical closure was achieved in all eyes postoperatively. The mean BCVA values increased compared to baseline (0.95±0.27) at postoperative first month (0.93±0.34), and third months (0.87±0.32), but this increase was not statistically significant (p=0.809, p=0.237, respectively). The mean BCVA values significantly improved compared to baseline at postoperative sixth months (0.54±0.28), and twelfth months (0.47±0.21) (p=0.000, p=0.000, respectively). The mean EZD diameter significantly decreased compared to baseline at all follow-up visits. No complications were observed.

**Conclusions:** Free ILM flap transplantation and the use of silicone-oil as an endotamponade provide an increase in BCVA levels, high anatomic closure rates, and improvement in EZD.

**Keywords:** Macular hole, Internal limiting membrane, Free flap, Silicone-oil, Ellipsoid zone.

## INTRODUCTION

After the determination of the effect of internal limiting membrane (ILM) in full-thickness macular hole (FTMH) pathogenesis,<sup>1,2</sup> ILM peeling has become the most important step of the surgical treatment of FTMHs.<sup>3</sup> The ILM peeling procedure combined with pars plana vitrectomy (PPV) provides closure of the FTMHs by both reducing the anteroposterior tractions between the vitreous and fovea with peeling of the posterior hyaloid, and by reducing tangential tractions with the peeling of the ILM.<sup>4,5</sup> It has been reported that ILM peeling combined with PPV surgery provides 90% closure in FTMHs.<sup>6,7,8</sup> However, the surgical success rates decrease to 40-80% in large FTMHs (diameter > 400 µm) or in myopic FTMHs

with the conventional ILM peeling method.<sup>9,10,11</sup> Therefore, modified ILM peeling methods have been developed in the surgical treatment of large, persistent, and recurrent FTMHs such as classical inverted ILM flap,<sup>12</sup> temporal inverted ILM flap,<sup>13</sup> and free ILM flap.<sup>14</sup>

In this retrospective study, we aimed to report anatomical and functional results in cases where we applied free ILM flap assisted with the perfluorocarbon liquid (PFCL), and silicone-oil endotamponade as primary or secondary surgery in large or persistent idiopathic FTMHs.

## MATERIALS AND METHODS

This retrospective, consecutive case series was conducted

1- MD, Basaksehir Cam and Sakura City Hospital, Department of Ophthalmology, Istanbul, Türkiye

2- Assist. Prof., MD, Babaeski State Hospital, Department of Ophthalmology, Kırklareli, Türkiye

3- Asist., MD, Babaeski State Hospital, Department of Ophthalmology, Kırklareli, Türkiye

Received: 01.11.2021

Accepted: 06.01.2022

Ret-Vit 2022; 31: 335-340

DOI:10.37845/ret.vit.2022.31.57

Correspondence Address:

Sadik Altan Ozal

Babaeski State Hospital, Department of Ophthalmology, Kırklareli, Türkiye

Phone: +90 284 236 0910

E-mail: altanozal@hotmail.com

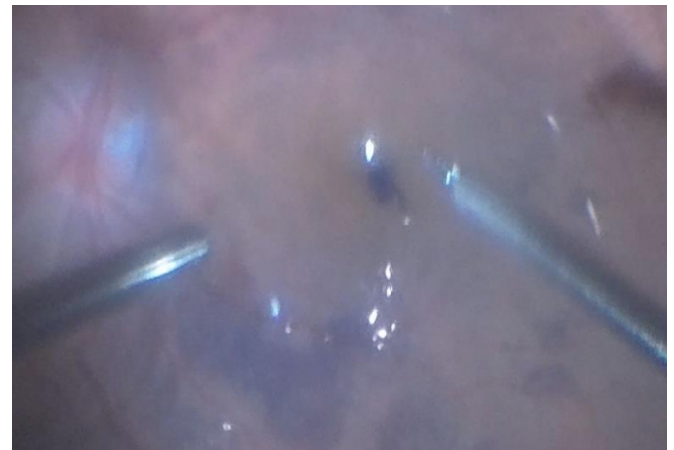with patients who underwent free ILM flap combined with PPV surgery due to idiopathic large or persistent FTMH (diameter > 400  $\mu\text{m}$ ) between January 2017 and December 2019 in the retina unit of our clinic. Patients with a dense cataract that prevents optical coherence tomography (OCT) measurement, aphakia, small or medium FTMH (diameter  $\leq$  400  $\mu\text{m}$ ), high myopia (> -6.0 diopter), a history of any other retinal disease, ocular trauma or glaucoma were excluded. Patients who did not have a follow-up period of at least 12 months after the surgical treatment were also excluded from the study. All patients were informed about the surgical treatment and the potential complications. Informed consent was obtained preoperatively from all patients. The study procedures were approved by the institutional review board of the hospital and adhered to the tenets of the Declaration of Helsinki. The study protocol was approved by the local ethics committee (TÜTF-BAEK 2021/44).

Detailed ophthalmologic examinations of the patients were performed before and after the surgical treatment. Best-corrected visual acuity (BCVA) was measured using a Snellen chart and transformed into a 'logarithm of minimum angle of resolution (LogMAR)' scale. All cases were assessed for the presence of FTMH using OCT (Cirrus HD 5000, Carl Zeiss Meditec AG, Jena, Germany) and the 'HD Cross' analysis program. The smallest diameter of FTMH values was measured manually. Large FTMH cases (diameter > 400  $\mu\text{m}$ ) were selected according to the classification defined by the International Vitreomacular Traction Study Group.<sup>15</sup> The diameter of the ellipsoid zone (EZ) disruption was measured manually. The FTMH base diameter was accepted as baseline EZ disruption. The medical records of the patients on the first month, the third month, the sixth month, and twelve months after the surgical treatment were evaluated. The rates of anatomical closure, BCVA values, and EZ disruption values were compared within the preoperative and postoperative periods, and complications due to surgical treatment were analyzed.

### Surgical technique

All surgical procedures were performed under subtenon anesthesia by the same experienced surgeon (SAO). The surgical technique included 25-gauge PPV using an Infinity Constellation (Alcon, Fort Worth, TX, USA) vitrectomy device. Combined phacovitrectomy (phacoemulsification and PPV) and intraocular one-piece lens implantation were performed in patients with any type of lens opacity. After intraocular lens implantation into the capsular bag, three 25-gauge trocars were inserted from the pars plana level to 4 mm behind the limbus. After core vitrectomy, the posterior hyaloid was stained with triamcinolone acetonide (TA, 2.5 mg/ml) and separated from the retina with the help

of the ocutome. ILM was stained with membrane blue-dual dye (DORC, Zuidland, Netherlands) applied for 30 seconds under fluid. PFCL was injected into the retina at the edge of the vascular arcades. An ILM flap 1.5 times the diameter of the FTMH was created from the residual ILM in persistent FTMHs where ILM peeling was performed in the previous surgery. In previously unoperated eyes, the ILM flap was prepared in the same way after peeling the ILM to the vascular arcades. The prepared free ILM flap was transferred and was tucked into the hole area under PFCL after irrigation was turned off (Figure 1). In the end, a gently air-fluid exchange has been done and silicone-oil of 5000 centistokes was used in all cases as an endotamponade. All of the sclerotomies were sutured with 7.0 Vicryl.



**Figure 1.** Intraoperative view of free internal limiting membrane flap transplantation.

Postoperatively, patients were instructed to posture with their faces down for one week. In the postoperative period, 0.5% topical moxifloxacin (Vigamox, Alcon Pharmaceuticals Plc, Fort Worth, TX, US) was applied for 2 weeks, and 1% topical prednisolone acetate (Pred-forte, Allergan, Dublin, IRL) was applied for 1 month.

### Statistical analysis

The "Statistical Package for Social Sciences version 25.0 for Windows" was used for statistical analysis. Before performing calculations on the non-qualitative data, the Shapiro-Wilk test was used to determine the conformity of the data with a normal distribution. For parametric and non-parametric variables, a paired t-test and a Wilcoxon signed-rank test were respectively used. A p-value less than 0.05 was accepted as statistically significant.

### RESULTS

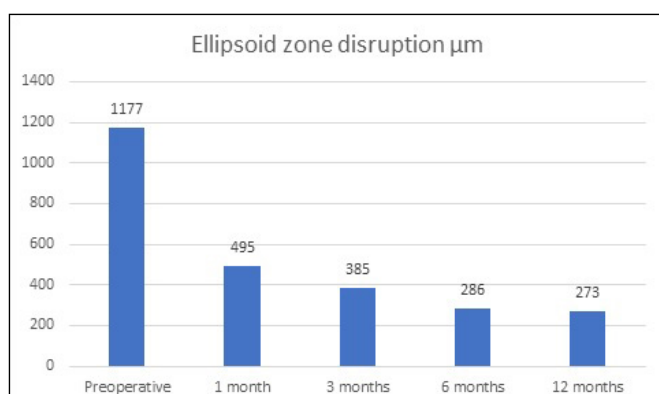
A total of 10 eyes of 10 patients were included in this study. Table 1 shows the individual characteristics and

**Table 1.** Findings for all patients included in the study.

Case Number	Age/Sex/ EyeBasa	Basal MH size (µm)	Preoperative lens status	Final lens status	Postoperative outcome	Preoperative BCVA (Snellen)	Final BCVA (Snellen)	Preoperative EZ disruption (µm)	Final EZ disruption (µm)	Additional ocular diseases	Complications	Follow-up (Months)
1	65/M/R	499	Phakic	Pseudophakic	Closed	0,2	0,8	1038	240	None	None	12
2	75/M/L	659	Pseudophakic	Pseudophakic	Closed	0,1	0,3	1268	654	None	None	12
3	70/F/R	629	Phakic	Pseudophakic	Closed	0,03	0,2	1648	829	None	None	12
4	67/F/R	529	Pseudophakic	Pseudophakic	Closed	0,15	0,33	829	250	None	None	24
5	76/F/R	459	Pseudophakic	Pseudophakic	Closed	0,1	0,2	1122	0	None	None	18
6	69/F/R	869	Pseudophakic	Pseudophakic	Closed	0,15	0,33	1448	329	None	None	18
7	71/F/L	539	Phakic	Pseudophakic	Closed	0,2	0,66	789	0	None	None	12
8	59/F/L	509	Pseudophakic	Pseudophakic	Closed	0,05	0,2	1070	0	None	None	12
9	72/F/R	752	Pseudophakic	Pseudophakic	Closed	0,1	0,3	1337	230	None	None	12
10	68/M/L	528	Pseudophakic	Pseudophakic	Closed	0,2	0,5	1224	205	None	None	12

M: Male, F: Female R:Right, L:Left MH: Macular hole BCVA:Best Corrected Visual Acuity EZ:Ellipsoid zone

findings for all cases. The mean age of the patients was  $69.20 \pm 4.94$  years (range 59-76 years). Seven patients (70.0%) were female, and 3 patients (30.0%) were male. The mean follow-up period of patients after surgical treatment was  $14.40 \pm 4.19$  months (range 12-24 months). In the preoperative period, 3 eyes (40.0%) were phakic, and 7 eyes (60.0%) were pseudophakic. In the 3 phakic eyes, a combined phacovitrectomy surgery was performed. Three eyes (30.0%) had persistent FTMH due to previous unsuccessful hole surgery. In 7 eyes (70.0%), free ILM flap surgery was performed as primary surgery. In the preoperative period, the mean diameter of the FTMHs was  $597.20 \pm 129.96$  µm (range 459-869 µm). The mean baseline EZ disruption diameter was  $1177.30 \pm 266$  µm (range 789-1648 µm). The mean EZ disruption diameter significantly decreased compared to baseline in all postoperative visits. Postoperative mean EZ disruption diameter was  $495.90 \pm 349.49$  µm ( $p = 0.005$ ) at 1 month,  $385.20 \pm 21.35$  µm ( $p = 0.000$ ) at 3 months,  $286.80 \pm 316.23$  µm ( $p = 0.005$ ) at 6 months, and  $273.70 \pm 276.70$  at 12 months ( $p = 0.000$ ) (Figure 2). Anatomical closure was achieved in the FTMHs of all eyes postoperatively (Figure 3). Silicone oil was removed from all eyes in the postoperative third month. The mean baseline BCVA was  $0.95 \pm 0.27$ . The



**Figure 2.** Mean values of ellipsoid zone disruption levels within one year after surgical treatment.

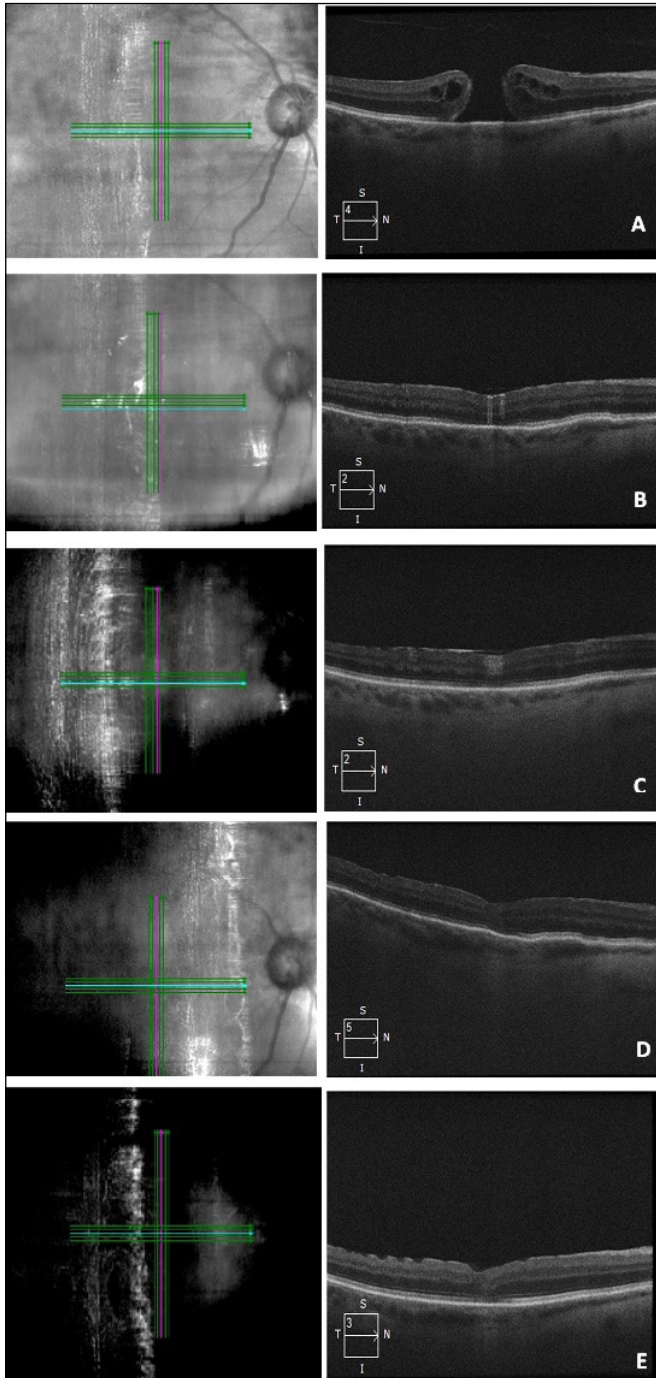
mean BCVA levels in the postoperative 1st and 3rd months increased compared to the baseline, but this increase was not statistically significant. In the postoperative 6th and 12th months, BCVA levels significantly improved compared to the baseline. Postoperative mean BCVA was  $0.93 \pm 0.34$  ( $p = 0.809$ ) at 1 month,  $0.87 \pm 0.32$  ( $p = 0.237$ ) at 3 months,  $0.54 \pm 0.28$  ( $p = 0.000$ ) at 6 months, and  $0.47 \pm 0.21$  ( $p = 0.000$ ) at 12 months (Figure 4). At the last visit, BCVA was improved in all eyes (100%). No complications were observed due to surgical treatment in the intraoperative and postoperative periods.

## DISCUSSION

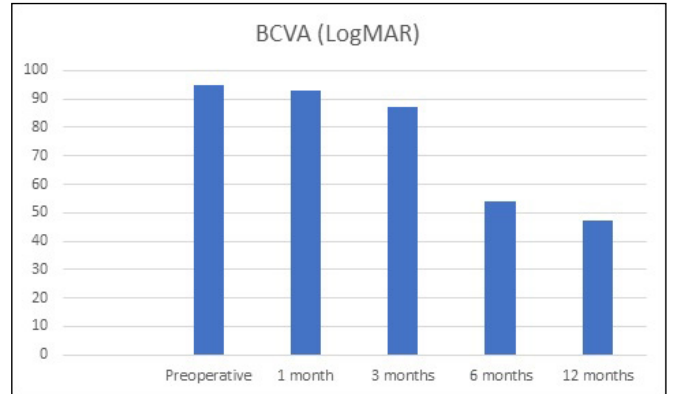
Anatomical closure and functional success rates obtained by conventional ILM peeling in large (> 400 µm) and persistent FTMH cases are not satisfactory.<sup>16</sup> This study included FTMHs that still did not close 3 months after the previous conventional ILM peeling, or large FTMHs over 400 µm in diameter. Michalewska et al. reported that they achieved 98% anatomic closure and good visual results with inverted ILM flap in large and persistent FTMHs.<sup>12</sup> They suggested that the inverted ILM flap formed a framework for the proliferation of Müller and glial cells. In recent years, different modified ILM flap techniques such as temporal inverted ILM flap, free ILM flap, double ILM insertion, floating ILM flap have been developed to increase anatomical and functional success rates.<sup>17</sup> Morizane et al. reported that they achieved anatomical closure with free ILM flap technique in all 10 eyes with refractory FTMHs.<sup>14</sup>

In the present study, we achieved anatomical and functional success in all eyes with the free ILM flap technique. The most difficult surgical step in the free ILM flap technique is the transfer of the flap to the MH area. At this stage, the loss of the flap and the inability to release the flap from the micro forceps complicates the surgical treatment.<sup>18</sup> In our technique, we observed that transferring the free ILM flap under the PFCL both prevented flap loss and facilitated its release from the micro forceps teeth. Also,





**Figure 3.** Full-thickness macular hole (FTMH) (499 μm) in the right eye of a 65-year-old male patient (Patient 1) (A). Optical coherence tomography (OCT) image in the postoperative first month shows that FTMH is anatomically closed (B). OCT image in the postoperative third month shows foveal hyperreflective lesion and silicone-oil hyperreflectivity (C). Postoperative sixth month OCT image shows that the foveal hyperreflective lesion has disappeared and the defect in the ellipsoid zone has decreased (D). OCT image in the postoperative twelve-month (E).



**Figure 4.** Mean values of best-corrected visual acuity levels within one year after surgical treatment.

we think that the prevention of fluid stream by turning-off irrigation during flap transfer, and the use of the light source as an auxiliary surgical tool facilitates surgical maneuvers. However, at this stage, the illumination of the light source was reduced to avoid light toxicity.<sup>8</sup> The use of viscoelastic and autologous blood plug has been reported in studies to prevent flap loss and flap displacement.<sup>19,20</sup> We did not require the use of viscoelastic and autologous blood plug in any of our cases, to minimize the risk of infection and surgical manipulations. Besides, there is a risk of unintentional aspiration of the ILM flap during the aspiration of the PFCL.<sup>18</sup> To prevent this complication, we placed the aspiration cannula within the edge of the PFCL bubble, rotated the eye, and gently aspirated the PFCL away from the fovea.

It has been reported that there is a less functional gain in large FTMHs and repeated surgeries are needed.<sup>12</sup> Bare RPE is the reason why less functional gain is obtained in recurrent surgery in large FTMHs compared to primary surgery. Ma et al. reported that 97.6% anatomical closure rates and good visual results with the free ILM flap technique, which they applied primarily surgically in macular holes larger than 500 μm.<sup>8</sup> In the same study, it was reported that recovery was obtained in the EZ in OCT measurement. In the present study, free ILM flap surgery was performed both as a second operation in eyes that had previously undergone unsuccessful surgery, and as primary surgery in large FTMHs over 400 μm. Although we achieved functional gain in all eyes in our study, we could not make a comparison between the two groups due to the small number of our cases. In the present surgical technique, we think that glial proliferation is stimulated by various growth factors with ILM peeling and that the free ILM flap provides a suitable environment for glial proliferation by creating a compartment that prevents fluid passage from the vitreous into the macular hole.<sup>17</sup>

Silicone-oil tamponade could be still an alternative in cases,

when there are no more efficient techniques or possibilities to treat with success persistent macular holes and large macular holes. The use of silicone-oil as endotamponade with ILM peeling increases the anatomical and functional success rates in persistent or large FTMHs.<sup>21</sup> It is thought that completely filling the vitreous cavity with silicone-oil in persistent or large macular holes, facilitates the absorption of subretinal fluid and provides a scaffold for glial proliferation. However, silicone-oil was not used as endotamponade in any of the studies in which free ILM flap was performed in the literature. We think that the use of silicone-oil as endotamponade in this study may also affect the high anatomical and functional success rates. Furthermore, in cases where gas is used as endotamponade, early resorption of gas and passage of aqueous humor into the vitreous cavity may lead to displacement of the free ILM flaps. We think that filling the vitreous cavity with the silicone-oil may prevent flap displacement in the early postoperative period. In cases where gas is used as endotamponade, early resorption of gas and passage of aqueous humor into the vitreous cavity may lead to displacement of the free ILM flaps. However, in the eyes of using silicone-oil as the endotamponade, silicone-oil needs to be removed with a second surgical procedure. In this study, silicone-oil was removed from all eyes in the postoperative third month. During the three months postoperatively, when silicone-oil remains in the eye, the increase in visual acuity may be more limited. In our study, we found that the visual gains increased after the silicone-oil was removed. Also, we did not observe any retinal pigment epithelium toxicity and any complications due to silicone-oil in any eyes.

Another important complication of ILM flap techniques is hyperproliferation of glial cells and scar formation. Hyperproliferation of the glial cells and scar formation reduce the EZ recovery and postoperative functional success rates.<sup>17</sup> We did not observe this complication in any of our patients who were followed up for at least one year with the appropriate amount of ILM flap transplantation. In the postoperative period, we observed that the foveal hyperreflective lesion disappeared in a few months on OCT in all eyes, the foveal contour was formed, and the EZ was healed. Besides, we think that as an advantage of using silicone-oil, it may prevent glial hyperproliferation and scar formation, and further comparative studies are needed on this subject.

The limitations of this study are the retrospective design of the study, the small number of patients, and limited postoperative follow-up period. In conclusion, silicone-oil endotamponade application with free ILM flap in the treatment of large or persistent idiopathic FTMHs is a safe method with high success rates in at least one year

of follow-up. However, further comparative studies with a higher number of patients and longer follow-up periods are needed.

## REFERENCES

- Gass JDM: Idiopathic senile macular hole: its early stages and pathogenesis. *Archives of ophthalmology* 1988, 106:629-39.
- Gass JDM: Reappraisal of biomicroscopic classification of stages of development of a macular hole. *American journal of ophthalmology* 1995, 119:752-9.
- Almony A, Nudleman E, Shah GK, Blinder KJ, Elliott DB, Mittra RA, Tewari A: Techniques, rationale, and outcomes of internal limiting membrane peeling. *Retina* 2012, 32:877-91.
- Rahimy E, McCannel CA: Impact of internal limiting membrane peeling on macular hole reopening: a systematic review and meta-analysis. *Retina* 2016, 36:679-87.
- Park DW, Sipperley JO, Sneed SR, Dugel PU, Jacobsen J: Macular hole surgery with internal-limiting membrane peeling and intravitreal air. *Ophthalmology* 1999, 106:1392-8.
- Haritoglou C, Gass CA, Schaumberger M, Gandorfer A, Ulbig MW, Kampik A: Long-term follow-up after macular hole surgery with internal limiting membrane peeling. *American journal of ophthalmology* 2002, 134:661-6.
- Beutel J, Dahmen G, Ziegler A, Hoerauf H: Internal limiting membrane peeling with indocyanine green or trypan blue in macular hole surgery: a randomized trial. *Archives of Ophthalmology* 2007, 125:326-32.
- Ma F-Y, Xi R-J, Chen P-F, Hao Y-H: Free autologous internal limiting membrane transplantation in the treatment of large macular hole. *International Journal of Ophthalmology* 2019, 12:848.
- Kusuhara S, Escaño MFT, Fujii S, Nakanishi Y, Tamura Y, Nagai A, Yamamoto H, Tsukahara Y, Negi A: Prediction of postoperative visual outcome based on hole configuration by optical coherence tomography in eyes with idiopathic macular holes. *American journal of ophthalmology* 2004, 138:709-16.
- Haritoglou C, Neubauer AS, Reiniger IW, Priglinger SG, Gass CA, Kampik A: Long-term functional outcome of macular hole surgery correlated to optical coherence tomography measurements. *Clinical & experimental ophthalmology* 2007, 35:208-13.
- Chhablani J, Khodani M, Hussein A, Bondalapati S, Rao HB, Narayanan R, Sudhalkar A: Role of macular hole angle in macular hole closure. *British Journal of Ophthalmology* 2015, 99:1634-8.
- Michalewska Z, Michalewski J, Adelman RA, Nawrocki J: Inverted internal limiting membrane flap technique for large macular holes. *Ophthalmology* 2010, 117:2018-25.
- Michalewska Z, Michalewski J, Dulciewska-Cichecka K, Adelman RA, Nawrocki J: Temporal inverted internal limiting membrane flap technique versus classic inverted internal limiting membrane flap technique: a comparative study. *Retina* 2015, 35:1844-50.
- Morizane Y, Shiraga F, Kimura S, Hosokawa M, Shiode Y,

- Kawata T, Hosogi M, Shirakata Y, Okanouchi T: Autologous transplantation of the internal limiting membrane for refractory macular holes. *American Journal of Ophthalmology* 2014, 157:861-869. e861.
15. Duker JS, Kaiser PK, Binder S, de Smet MD, Gaudric A, Reichel E, Sadda SR, Sebag J, Spaide RF, Stalmans P: The International Vitreomacular Traction Study Group classification of vitreomacular adhesion, traction, and macular hole. *Ophthalmology* 2013, 120:2611-9.
16. Yu Y, Liang X, Wang Z, Wang J, Liu W: Clinical and morphological comparisons of idiopathic macular holes between stage 3 and stage 4. *Graefe's Archive for Clinical and Experimental Ophthalmology* 2018, 256:2327-33.
17. Xu Q, Luan J: Internal limiting membrane flap technique in macular hole surgery. *International Journal of Ophthalmology* 2020, 13:822.
18. Wu A-L, Chuang L-H, Chen K-J, Yeung L, Wang N-K, Liu L, Hwang Y-S, Wu W-C, Lai C-C: Perfluoro-n-octane-assisted autologous internal limiting membrane plug for refractory macular hole surgery. *International ophthalmology* 2019, 39:2767-73.
19. Lai C-C, Chen Y-P, Wang N-K, Chuang L-H, Liu L, Chen K-J, Hwang Y-S, Wu W-C, Chen T-L: Vitrectomy with internal limiting membrane repositioning and autologous blood for macular hole retinal detachment in highly myopic eyes. *Ophthalmology* 2015, 122:1889-98.
20. Song Z, Li M, Liu J, Hu X, Hu Z, Chen D: Viscoat assisted inverted internal limiting membrane flap technique for large macular holes associated with high myopia. *Journal of Ophthalmology* 2016, 2016.
21. Pieczynski J, Kuklo P, Grzybowski A: Pars plana vitrectomy with silicone oil tamponade for primary and secondary macular hole closure: Is it still a useful procedure? *European journal of ophthalmology* 2018, 28:503-14.