

# Relationship Between Chronic Obstructive Pulmonary Disease and Severity of Diabetic Retinopathy

Ayşe Güzin Taşlıpınar Uzel<sup>1</sup>, Erdoğan Yaşar<sup>2</sup>, İbrahim Güven Coşkun<sup>3</sup>, Serhat Sayın<sup>4</sup>, Mehmet Murat Uzel<sup>5</sup>

## ABSTRACT

**Purpose:** The negative effects of chronic obstructive pulmonary disease (COPD) on diabetes mellitus (DM) patients are known. For these reasons, we aimed to investigate the effect of COPD on the severity of diabetic retinopathy (DRP) in patients with DM.

**Materials and Methods:** This prospective cross-sectional study included one-hundred and fifty-six eyes of 156 patients with COPD and DM. Multinomial logistic regression models were applied to evaluate the independent relationships between DRP and COPD, including adjusting for patients' characteristics.

**Results:** After adjustment for potential confounders, patients with low-level COPD were found to have less PDR and severe PDR. (RRR 0.01 95% CI 0.01-0.03, RRR 0.01 95% CI 0.01-0.08, respectively).

**Conclusion:** The findings suggest an increased risk of DRP severity in patients with severe COPD. Ophthalmologists following these patients should consider the relationship between COPD and DRP.

**Keywords:** chronic obstructive pulmonary disease; diabetes mellitus; diabetic retinopathy severity; multinomial logistic regression.

## INTRODUCTION

Diabetic retinopathy (DRP) is a microvascular complication of diabetes mellitus (DM) resulting in severe visual loss. The factors affecting the development of diabetic retinopathy have not been identified. However, studies have demonstrated the effects of hyperglycemia, dyslipidemia, hypertension, inflammation, and retinal neurodegeneration in the development of DRP<sup>1-3</sup>.

Chronic obstructive pulmonary disease (COPD) is a lung disease characterized by progressive airway obstruction in which an abnormal inflammatory response to harmful particles and gases occurs<sup>4</sup>. Today, it is a systemic disease affecting the entire body. Tissue hypoxia, smoking, and secreted cytokines contribute to the emergence of systemic effects<sup>5</sup>. Although the coexistence of COPD and DM has not been established, and it is evident that the prognosis of these two diseases is influenced by one another. In particular, COPD has been shown to increase the development of DM and was also associated with worse outcomes of COPD<sup>6, 7</sup>.

Many studies have been conducted regarding the effects of

COPD on eye tissues. COPD has been shown to reduce the functional capacity of the corneal endothelium and lower the response to surgical stress<sup>8</sup>. It has been shown that subfoveal choroidal thickness decreases, and retinal nerve fiber layer thickness (RNFL) change occur in COPD<sup>9, 10</sup>. Decreased retrobulbar blood flow, parafoveal vascular density and subfoveal choroidal thickness are other significant effects of COPD on the eye<sup>11, 12, 13</sup>.

In light of these findings, the severity of DRP may be adversely affected in COPD patients. Therefore, we aimed to investigate the effect of COPD on the severity of DRP in DM patients.

## MATERIALS AND METHODS

This prospective cross-sectional study consists of 156 DM and COPD patients examined at the Aksaray University School of Medicine, ophthalmology department. All study procedures were conducted per the Declaration of Helsinki, and informed consent was obtained from all participants.

1- MD., Ufuk University School of Medicine, Department of Ophthalmology, Ankara, Türkiye

2- Assoc. Prof., Parkhayat Hospital, Department of Ophthalmology, Afyonkarahisar, Türkiye

3- MD., Afyonkarahisar State Hospital, Department of Respiratory Medicine, Afyonkarahisar, Türkiye

4- Assoc. Prof., Aksaray University School of Medicine, Department of Internal Medicine, Aksaray, Türkiye

5- Assoc. Prof., Balıkesir University School of Medicine, Department of Ophthalmology, Balıkesir, Türkiye

Received: 18.04.2022

Accepted: 16.09.2022

*J Ret-Vit* 2023; 32: 97-102

DOI: 10.37845/ret.vit.2023.32.17

**Correspondence Address:**

Ayşe Güzin Taşlıpınar Uzel  
Ufuk University School of Medicine, Department of Ophthalmology,  
Ankara, Türkiye

**Phone:** +90 505 824 7599

**E-mail:** agtaslipinar@gmail.com

This study was approved by the Ethical Committee of the Aksaray University School of Medicine.

Detailed ophthalmologic examinations, the coexistence of systemic diseases, duration of DM, smoking history, HbA1c levels, body mass index (BMI), COPD stages, and treatment protocols were recorded. Those with HbA1c levels below 7 were considered as well-controlled DM. The duration of DM was grouped over 5-year periods. The diagnosis of DRP was based on a digital fundus camera (grading of fundus photographs by masked graders) (Zeiss Visucam NM / FA, Carl Zeiss Meditec, Inc., Jena, Germany). The severity of DRP was categorized as no DRP, mild non-proliferative diabetic retinopathy (NPDR), moderate NPDR, severe NPDR, or proliferative diabetic retinopathy (PDR) according to the Early Treatment Diabetic Retinopathy Study protocol.<sup>14</sup> When there was disagreement about the severity of DRP, an ophthalmologist experienced in DRP resolved this problem. If the retinopathy is asymmetrical, the worst eye was included in the study. COPD patients were stratified into four stages according to GOLD (Global Initiative for Obstructive Lung Disease) criteria.<sup>4</sup>

Statistical analysis was performed using SPSS v.21.0 for Windows (SPSS, Inc., Chicago, IL, USA). The normality of the data distribution was evaluated by the Shapiro-Wilk test. Because the data were normally distributed, an independent-t-test was used to compare the results. In addition, multinomial logistic regression models were applied to evaluate the independent relationships between DRP and COPD, including adjusting for patients' characteristics. Relative risk ratios (RRR) and 95% confidence intervals (CI) are reported. All values are provided as mean  $\pm$  SD. The level of statistical significance was set at  $p < 0.05$ .

## RESULTS

Of the 156 patients included in the analysis, 44 (28.2%) had no DRP, 20 (12.8%) had mild non-proliferative diabetic retinopathy (NPDR), 25 (16.1%) had moderate NPDR, 31 (19.8%) had severe NPDR, and 36 (23.1%) had proliferative diabetic retinopathy (PDR). The mean age of the patients was  $61.83 \pm 6.83$  years, and mean DM duration was  $11.76 \pm 5.11$  years, the mean HbA1c levels were  $7.16 \pm 1.53$ , and the mean BMI rates were  $31 \pm 3.24$ . Patient characteristics are given in Table 1. The distribution of patients according to COPD stage is shown in Figure 1. According to the univariable analysis, the risk of PDR and severe NPDR is reduced in low-level COPD (Table 2). After adjustment for potential confounders, patients with low-level COPD were found to have less PDR and severe PDR. (Table 3). In addition, shorter duration of diabetes and HbA1c levels below 7 are influential factors in decreasing DRP severity.

## DISCUSSION

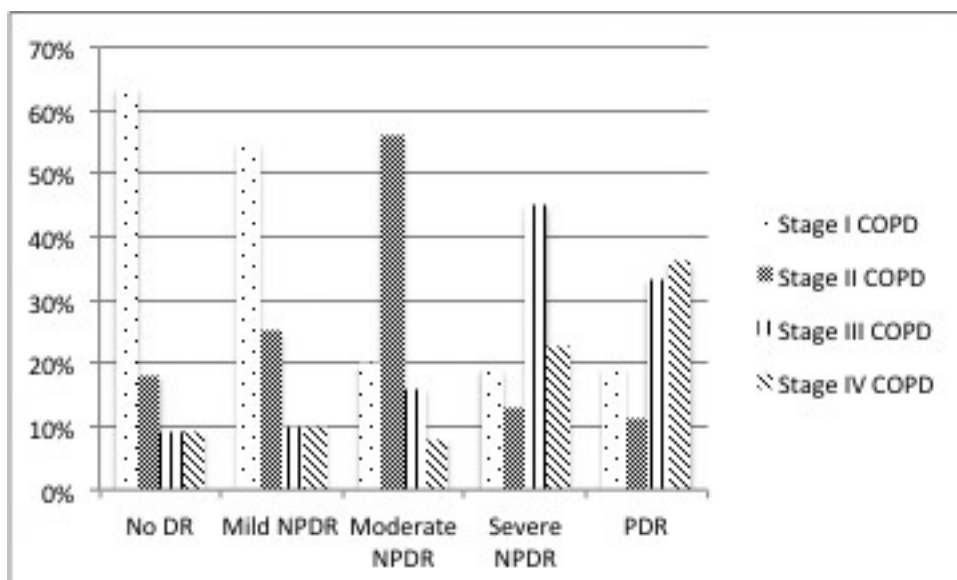
According to the results of our study, there is a relationship between the stage of COPD and the severity of DRP. To our knowledge, this is the first study to investigate the relationship between COPD and DRP severity. In addition, we found that well-controlled DM and low DM duration were associated with low DRP severity.

There are various studies on the effects of COPD on the eye. In one study, COPD impaired corneal endothelial morphology and function.<sup>8</sup> Although the underlying mechanism is unknown, and the authors state that systemic oxidative stress, inflammation, hypoxia, and corticosteroid use caused by COPD cause these results.<sup>8</sup> In several works, it was concluded that subfoveal choroidal thickness decreased in COPD.<sup>9,10</sup> This observation was interpreted as chronic hypoxia and hypercapnia caused by COPD affecting the retinal vessels. Another study has demonstrated that

**Table 1:** Patient's Characteristics

	No DRP (n=44)	Mild NPDR (n=20)	Moderate NPDR (n=25)	Severe NPDR (n=31)	PDR (n=36)
Age (years)	62.3 $\pm$ 6.9	61.1 $\pm$ 7.0	61.0 $\pm$ 6.9	61.6 $\pm$ 6.9	62.3 $\pm$ 6.7
Gender (Female)	15(%34.1)	11(%55)	10(%40)	13(%41.9)	7(%19.4)
BMI (kg/m <sup>2</sup> )	30 $\pm$ 3.3	32.1 $\pm$ 2.1	31.6 $\pm$ 3.4	30.4 $\pm$ 3.5	31.6 $\pm$ 2.9
Smoker	28 (%63.6)	14 (%70)	18 (%72)	22 (%71)	25 (%69.4)
Diabetes duration (years)	8.9 $\pm$ 3.9	7.9 $\pm$ 1.3	9.8 $\pm$ 2.2	15.4 $\pm$ 5.1	15.4 $\pm$ 4.7
Hypertension	38 (%86.4)	18 (%90)	22 (%88)	26 (%83.9)	29 (%80.6)
Dyslipidemia	15 (%34)	10 (%50)	11 (%44)	13 (%41)	12 (%33)

DRP: diabetic retinopathy; NPDR: nonproliferative diabetic retinopathy; PDR: proliferative retinopathy; BMI: body-mass index;



**Figure 1:** The distribution of patients according to chronic obstructive pulmonary disease stage

**Table 2:** Univariable multinomial logistic regression models for DRP

COPD	Mild NPDR RRR (95% CI) (n=20)	Moderate NPDR RRR (95% CI) (n=25)	Severe NPDR RRR (95% CI) (n=31)	PDR RRR (95% CI) (n=36)
Stage 1	0.78 (0.12-4.92)	0.35 (0.05-2.50)	<b>0.12 (0.02-0.55)</b>	<b>0.07 (0.01-0.31)</b>
Stage 2	1.25 (0.16-9.53)	3.5 (0.52-23.55)	0.28 (0.05-1.59)	<b>0.15 (0.03-0.79)</b>
Stage 3	1 (0.09-11.02)	2 (0.22-17.89)	2 (0.38-10.48)	0.92 (0.18-4.53)
Stage 4	1	1	1	1
DM duration				
5-10	0.25 (0.04-1.57)	0.16 (0.01-1.43)	<b>0.06 (0.01-0.29)</b>	<b>0.01 (0.01-0.12)</b>
10-15	0.75 (0.11-5.10)	2.62 (0.35-19.18)	<b>0.12 (0.02-0.71)</b>	0.34 (0.07-1.63)
15-20	0.66 (0.08-5.12)	1.50 (0.18-12.45)	0.33 (0.06-1.73)	0.45 (0.09-2.29)
>20	1	1	1	1
HbA1c				
<7	0.62 (0.20-1.89)	<b>0.05 (0.01-0.22)</b>	<b>0.12 (0.04-0.35)</b>	<b>0.05 (0.01-0.17)</b>
>7	1	1	1	1

Estimates with p values ≤0.05 are shown in boldface  
 RRR: relative risk ratio; DRP: diabetic retinopathy; COPD: chronic obstructive pulmonary disease; DM: diabetes mellitus; NPDR: nonproliferative diabetic retinopathy; PDR: proliferative diabetic retinopathy

retrobulbar blood flow is reduced in COPD.<sup>11</sup> In addition, this study found a relationship between the progression of COPD and decreased retrobulbar blood flow.<sup>11</sup> Increased endothelin, a potent vasoconstrictor, has been demonstrated in COPD<sup>15</sup>. A vasoconstrictor effect is also associated with increased reactive oxygen species (ROS)<sup>16</sup>. Increased ROS may also contribute to blood flow reduction and nerve damage. Studies also illustrate that RNFL thickness decreases in COPD via similar mechanisms<sup>9, 17</sup>. Alim et al. also demonstrated the reduction in subfoveal choroidal

thickness, which they cited as a potential effect of chronic hypoxemia due to COPD<sup>13</sup>. Kergoat et al. examined retinal ganglion cell susceptibility to mild hypoxemia and showed decreased arterial blood pressure and reduced ganglion cell function<sup>18</sup>. The authors concluded that neural function during hypoxia was affected due to metabolic changes and could not be compensated correctly by vascular regulation of the inner retina<sup>18</sup>. In the study of Alkan et al., it was determined that vascular density decreased in the parafoveal area with OCT angiography. This has been

**Table 3:** Multivariable multinomial logistic regression models for DRP

	Mild NPDR RRR (95% CI) (n=20)	Moderate NPDR RRR (95% CI) (n=25)	Severe NPDR RRR (95% CI) (n=31)	PDR RRR (95% CI) (n=36)
<b>Age</b>				
50-60	1.49 (0.24-9.10)	0.94 (0.12-7.17)	0.47 (0.05-3.78)	0.57 (0.06-5.03)
60-70	0.49 (0.07-3.29)	0.76 (0.09-6.16)	0.88 (0.11-6.84)	1.83 (0.21-15.64)
>70	1	1	1	1
<b>Sex</b>				
Female	2.24 (0.54-9.24)	1.02 (0.23-4.59)	1.37 (0.30-6.37)	0.29 (0.05-1.63)
Male	1	1	1	1
<b>BMI</b>				
25-30	0.16 (0.01-4.37)	0.10 (0.01-2.46)	0.89 (0.02-38.52)	0.11 (0.01-3.24)
30-35	2.40 (0.11-50.96)	0.47 (0.02-10.25)	2.92 (0.07-99.74)	0.89 (0.03-22.96)
>40	1	1	1	1
<b>Smoking status</b>				
Never	0.25 (0.05-1.12)	0.29 (0.06-1.44)	0.15 (0.03-0.73)	0.14 (0.02-0.77)
Current/former	1	1	1	1
<b>Comorbidities</b>				
No	0.68(0.09-5.06)	1.07 (0.14-8.13)	0.80 (0.10-0.73)	1.46 (0.17-12.02)
Yes	1	1	1	1
<b>COPD stage</b>				
Stage 1	0.41 (0.04-4.24)	0.09 (0.01-1.38)	<b>0.01 (0.01-0.08)</b>	<b>0.01 (0.01-0.03)</b>
Stage 2	0.94 (0.07-11.81)	2.07 (0.18-23.38)	<b>0.10 (0.01-1.02)</b>	<b>0.04 (0.01-0.50)</b>
Stage 3	0.92 (0.05-15.41)	1.31 (0.08-20.17)	0.48 (0.04-4.96)	0.14 (0.01-1.73)
Stage 4	1	1	1	1
<b>DM duration</b>				
5-10	<b>0.10 (0.01-1.08)</b>	<b>0.05 (0.01-0.79)</b>	<b>0.01 (0.01-0.17)</b>	<b>0.01 (0.01-0.62)</b>
10-15	0.35 (0.03-3.78)	0.32 (0.02-4.41)	<b>0.02 (0.02-0.27)</b>	<b>0.02 (0.01-0.16)</b>
15-20	0.54 (0.05-5.66)	1.49 (0.11-20.13)	0.54 (0.05-5.56)	0.40 (0.03-4.15)
>20	1	1	1	1
<b>HbA1c</b>				
<7	1.11 (0.27-9.24)	<b>0.11 (0.02-0.62)</b>	<b>0.06 (0.01-0.31)</b>	<b>0.02 (0.01-0.17)</b>
>7	1	1	1	1

Estimates with p values  $\leq 0.05$  are shown in boldface

RRR: relative risk ratio; DRP: diabetic retinopathy; COPD: chronic obstructive pulmonary disease; DM: diabetes mellitus; NPDR: nonproliferative diabetic retinopathy; PDR: proliferative diabetic retinopathy; BMI: body mass index

attributed to hypoxemia and endothelial dysfunction caused by COPD<sup>12</sup>.

The mechanism for the development of DRP is unclear. Hyperglycemia and the resulting pericyte loss are the most critical factors initiating endothelial damage<sup>19</sup>. Initially, autoregulation results in vascular dilatation, but vascular occlusion and retinal hypoxia develop over time<sup>20</sup>. Leukostasis due to inflammation also increases

this occlusion<sup>21</sup>. Poor control of blood glucose level and duration of DM is thought to be the most influential factors in the development of DRP<sup>2</sup>. Hyperlipidemia and hypertension affect the development of DR<sup>1,2</sup>. But it has been shown that reasonable hypertension control does not prevent such DRP development<sup>22</sup>. Retinal venous oxygen saturation was higher in DRP, attributed to the reduction of oxygen transfer to the tissues and the acceleration of blood flow from the stent<sup>23</sup>. When the relationship between

COPD and DM is considered, it is stated that DM is observed more in COPD patients<sup>24, 25</sup>. It was determined that more DM developed, particularly in GOLD stages 3-4. COPD may lead to systemic inflammation and increase IL-6, which plays a role in insulin resistance<sup>26</sup>. To our knowledge, the relationship between DRP and COPD has not been previously discussed. However, the relationship between obstructive sleep apnea (OSA) and DRP has been discussed in many studies<sup>27-29</sup>. Chang et al. showed that severe OSA increases the risk and severity of DRP<sup>29</sup>. OSA leads to increased insulin resistance and poor glucose control<sup>30, 31</sup>. In addition, elevated inflammatory cytokine levels secondary to transient hypoxemia during apnoea periods may accelerate damage to the retinal vasculature and the onset of DRP<sup>32</sup>. For similar reasons, the severity of DRP may be increased in COPD patients. One of the most important causes of this condition is systemic inflammation in COPD<sup>5</sup>. As a result, vascular occlusion and leukostasis may effectively develop DRP. Hypoxia in COPD further impairs already impaired tissue nutrition<sup>11</sup>. COPD may also have indirect effects on DRP development. Smoking, hypertension, and obesity are more common in these patients. In addition, insulin resistance increases in COPD, and blood glucose levels are difficult to control<sup>26</sup>. All these causes may lead to an increase in the severity of DRP in COPD and DM.

One of the study's limitations is that the patient's metabolic control was evaluated with a single HbA1c measurement because it is a cross-sectional study. The most important limiting factor in our study was the number of patients. Data obtained in large groups with multi-center studies may allow more precise results.

Consequently, COPD can lead to an increase in DRP severity. Close monitoring of COPD patients, effective control of blood glucose levels, and informing patients about this may effectively prevent or reduce the severity of DRP.

### Acknowledgements

Our presentation was approved by the Ethics Committee of Aksaray University School of Medicine, Aksaray, Turkey. Neither this manuscript nor one with similar content has been published or is being considered for publication elsewhere. The named authors of this manuscript received no financial support or funds and have no financial interests related to this manuscript

### REFERENCES

1. Van Leiden HA, Dekker JM, Moll AC, et al. Blood pressure, lipids, and obesity are associated with retinopathy: the Hoorn study. *Diabetes Care* 2002;25:1320-5.
2. Yau JW, Rogers SL, Kawasaki R, et al. Global prevalence and major risk factors of diabetic retinopathy. *Diabetes Care* 2012;35:556-64.
3. Barber AJ, Lieth E, Khin SA, et al. Neural apoptosis in the retina during experimental and human diabetes. Early-onset and effect of insulin. *J. Clin. Investig* 1998;102:783-91.
4. Vogelmeier CF, Criner GJ, Martinez FJ, et al. Global Strategy for the Diagnosis, Management, and Prevention of Chronic Obstructive Lung Disease 2017 Report. GOLD Executive Summary. *Am J Respir Crit Care Med* 2017;195:557-82.
5. Vernooy JH, Kucukaycan M, Jacobs JA, et al. Local and systemic inflammation in patients with chronic obstructive pulmonary disease: soluble tumor necrosis factor receptors are increased in sputum. *Am J Respir Crit Care Med* 2002;166:1218-24.
6. Gläser S, Krüger S, Merkel M, et al. Chronic obstructive pulmonary disease and diabetes mellitus: a systematic review of the literature. *Respiration*. 2015;89:253-64.
7. Ho TW, Huang CT, Ruan SY, et al. Diabetes mellitus in patients with chronic obstructive pulmonary disease-The impact on mortality. *PLoS One*. 2017;12:e0175794.
8. Soler N, Romero-Aroca P, Gris O, et al. Corneal endothelial changes in patients with chronic obstructive pulmonary disease and corneal vulnerability to cataract surgery. *J Cataract Refract Surg*. 2015;41:313-9
9. Ozcimen M, Sakarya Y, Kurtipek E, et al. Peripapillary choroidal thickness in patients with chronic obstructive pulmonary disease. *Cutan ocul Toxicol*. 2016;35:26-30.
10. Gok M, Ozer MA, Ozen S, et al. The evaluation of retinal and choroidal structural changes by optic coherence tomography in patients with chronic obstructive pulmonary disease. *Curr Eye Res* 2018;43:116-21.
11. Celik C, Tokgöz O, Serifoglu L, et al. Color doppler evaluation of the retrobulbar hemodynamic changes in chronic obstructive pulmonary disease: COPD and retrobulbar hemodynamic changes. *Ultrason Imaging* 2004;36:177-86.
12. Alkan AA, Duzgun E, Karapapak M, et al. Retinal Vascular Changes in Patients with Chronic Obstructive Pulmonary Disease: An Optical Coherence Tomography Angiography Study. *Sisli Etfal Hastan Tip Bul*. 2021;55:210-6.
13. Alim S, Demir HD, Yilmaz A, et al. To Evaluate the Effect of Chronic Obstructive Pulmonary Disease on Retinal and Choroidal Thicknesses Measured by Optical Coherence Tomography. *J Ophthalmol*. 2019;2019:7463815.
14. Grading diabetic retinopathy from stereoscopic color fundus photographs--an extension of the modified Airlie House classification. ETDRS report number 10. Early Treatment Diabetic Retinopathy Study Research Group. *Ophthalmology* 1991;98:786-806.
15. Roland M, Bhowmik A, Sapsford RJ, et al. Sputum and plasma endothelin-1 levels in exacerbations of chronic obstructive pulmonary disease. *Thorax* 2001;56:30-5.
16. Marginean C, Popescu MS, Vladaia M, et al. Involvement of oxidative stress in COPD. *Curr Health Sci J* 2018;44:48-55
17. Ugurlu E, Pekel G, Altinisik G, et al. New aspect for systemic effects of COPD: eye findings. *Clin Respir J* 2018;12:247-52

18. Kergoat H, Herard ME, Lemay M. RGC sensitivity to mild systemic hypoxia. *Invest Ophthalmol Vis Sci* 2006;47: 5423-7.
19. Ejaz, S, Chekarova, I, Ejaz A, et al. Importance of pericytes and mechanisms of pericyte loss during diabetes retinopathy. *Diabetes Obes. Metab* 2008;10:53-63.
20. Bek, T. Diameter changes of retinal vessels in diabetic retinopathy. *Curr. Diabetes Rep.* 2017;17:82.
21. Miyamoto K, Hiroshima N, Tsujikawa A, et al. In vivo demonstration of increased leukocyte entrapment in retinal microcirculation of diabetic rats. *Investig. Ophthalmol. Vis. Sci* 1998;39:2190-4.
22. ACCORD Study Group, et al. Effects of medical therapies on retinopathy progression in type 2 diabetes. *N Engl J Med* 2010;363:233-44.
23. Hammer M, Visser W, Riemer T, et al. Diabetic patients with retinopathy show increased retinal venous oxygen saturation. *Graefes Arch Clin Exp Ophthalmol* 2009;247:1025-30
24. Parappil A, Depczynski B, Collett P, et al. Effect of comorbid diabetes on length of stay and risk of death in patients admitted with acute exacerbations of COPD. *Respirology* 2010;15:918-22.
25. Rogliani P, Calzetta L, Segreti A, et al. Diabetes mellitus among outpatients with COPD attending a university hospital. *Acta Diabetol* 2014;51:933-40.
26. Bolton CE, Evans M, Ionescu AA, et al. Insulin resistance and inflammation - a further systemic complication of COPD. *COPD* 2007;4:121-6.
27. West SD, Groves DC, Lipinski HJ, et al. The prevalence of retinopathy in men with type 2 diabetes and obstructive sleep apnoea. *Diabet Med* 2010;27:423-30.
28. Hosseini S, Bailey B, Price R, et al. The association between obstructive sleep apnoea syndrome and micro-vascular complications in well-controlled diabetic patients. *Mil Med* 2010;175:913-6.
29. Chang AC, Fox TP, Wang S, et al. Relationship between obstructive sleep apnoea and the presence and severity of diabetic retinopathy. *Retina* 2018;38:2197-206
30. Resnick HE, Redline S, Shahar E, et al. Diabetes and sleep disturbances: findings from the Sleep Heart Health Study. *Diabetes Care* 2003;26:702-9.
31. Foster GD, Sanders MH, Millman R, et al. Obstructive sleep apnoea among obese patients with type 2 diabetes. *Diabetes Care* 2009;32:1017-9.
32. Nannapaneni S, Ramar K, Surani S. Effect of obstructive sleep apnoea on type 2 diabetes mellitus: a comprehensive literature review. *World J Diabetes* 2013;4:238-44.